Whipplova bolezen: redka in tiha ubijalka, skrita v vsakdanjosti – prikaz primera

Whipple's Disease: A Rare but Deadly Condition Hidden in Plain Sight – A Case Report

Avtor / Author

Sandra Burja Piko[1], Natalija Planinc Strunjas[2], Jernej Grmek[3], Nina Ostasevski Fernandez[3], Marko Miklic[3]

Ustanova / Institute

[1]Univerzitetni klinični center Maribor, Klinika za interno medicino, Klinični oddelek za kardiologijo in angiologijo, Maribor, Slovenija; [2]Univerzitetni klinični center Ljubljana, Klinika za infekcijske bolezni in vročinska stanja, Oddelek intenzivne terapije, Ljubljana, Slovenija; [3]Univerzitetni klinični center Ljubljana, Interna klinika, Klinični oddelek za žilne bolezni, Ljubljana, Slovenija;

[1]University Medical Centre Maribor, University Division of Internal Medicine, University Department of Cardiology and Angiology, Maribor, Slovenia; [2]University Medical Centre Ljubljana, Division of Infectious Diseases Intensive Care Unit, Ljubljana, Slovenija; [3]University Medical Centre Ljubljana, Division of Internal Medicine, Clinical Department of Vascular Diseases Intensive Care Unit, Ljubljana, Slovenija;

Ključne besede:
Whipplova bolezen, Tropheryma whipplei, globoka venska tromboza, pljučna hipertenzija, ehokardiografija

Key words:
Whipple's disease, Tropheryma whipplei, deep vein thrombosis, pulmonary hypertension, echocardiography

Članek prispel / Received
21. 8. 2025
Članek sprejet / Accepted
9. 9. 2026

Naslov za dopisovanje / Correspondence
Sandra Burja Piko
sandra.burja@gmail.com

Izvleček

Namen: *Whipplova bolezen je zelo redka sistemska vnetna bolezen, ki jo povzroča okužba z bakterijo Tropheryma whipplei. Vsako leto je po svetu potrjenih približno 12 novih primerov. Klasična tetrada simptomov je sestavljena iz artralgije, anoreksije, bolečin v trebuhu in driske, vendar lahko atipična manifestacija bolezni zakasni postavitev diagnoze. Diagnostični kriteriji, s katerimi bolezen potrdimo, zahtevajo pozitivne rezultate biopsije sluznice želodca in dvanajstnika. Bolniki se po zdravljenju z antibiotiki pogosto precej hitro izboljšajo; v primeru nezdravljene bolezni pa je le-ta smrtna.*

Poročilo o primeru: *V tem kliničnem primeru obravnavamo 81-letne-*

Abstract

Background: *Whipple's disease, a rare systemic infection caused by the bacterium Tropheryma whipplei, is confirmed annually in approximately 12 new cases worldwide. The classical tetrad of symptoms consists of arthralgia, anorexia, abdominal pain, and diarrhoea; however, atypical manifestations may delay diagnosis.*

Diagnostic criteria require positive results following a stomach and duodenal mucosa biopsy. Patients often improve quite rapidly after antibiotic treatment. However, if left untreated, Whipple's disease is lethal.

Case report: *We present the case of an 81-year-old man with progressive weakness, malnutrition, chron-*

https://doi.org/10.18690/actabiomed.310, CC BY 4.0
© 2026 Avtor(ji) / The Author(s)

ga bolnika s progresivno šibkostjo, malnutricijo, kroničnim vnetjem, globoko vensko trombozo in pljučno hipertenzijo brez pljučne embolije. Ehokardiografija je pokazala obremenitev desnega prekata in povečan desni prekat. Z uporabo testiranja s polimerazno verižno reakcijo (PCR) smo dokazali prisotnost Tropheryme whipplei v plevralni tekočini, blatu in slini, prisotnost v bioptatu duodenalne sluznice pa je dokončno potrdila diagnozo. Po zdravljenju s ceftriaksonom intravensko ter dolgotrajnim peroralnim zdravljenjem s sulfametoksazol-trimetoprimom je bolnik doživel izrazito klinično izboljšanje z normalizacijo vnetnih pokazateljev in izboljšanjem fizičnega stanja.

Zaključek: *S tem kliničnim primerom nameravamo izpostaviti Whipplovo bolezen kot eno izmed možnih diagnoz, katero je potrebno upoštevati pri bolnikih s sistemskimi simptomi in atipičnimi kardiovaskularnimi manifestacijami.*

ic inflammation, deep vein thrombosis, and pulmonary hypertension without pulmonary embolism. Echocardiography revealed right ventricular strain and an enlarged right ventricle.

Polymerase chain reaction detected Tropheryma whipplei in pleural fluid, stool, and saliva, while duodenal biopsy confirmed the diagnosis. Following treatment with ceftriaxone and long-term oral trimethoprim-sulfamethoxazole antibiotics, the patient experienced marked clinical improvement with normalization of inflammatory markers and improved functional status.

Conclusion: *This case highlights the importance of considering Whipple's disease in patients with unexplained systemic symptoms and atypical cardiovascular manifestations.*

INTRODUCTION

Whipple's disease (WD) is a rare multisystem infection caused by Tropheryma whipplei (1-6). The prevalence of WD is approximately 3/1,000,000, mainly affecting middle-aged Caucasian men (mean onset 55 years; male:female ratio is about 8:1), and is associated with human leukocyte antigen B27 (1,3,5-7). WD was first described in 1907, and both culture and polymerase chain reaction (PCR) diagnostic methods advanced in the 1990s (1-6). Tropheryma whipplei is detectable not only in duodenal biopsies, but also in saliva, blood, stool, cardiac valves, synovial fluid, cerebrospinal fluid (CSF), brain and multiple organs (1,9). Transmission of the disease is likely by the fecal–oral route via contaminated water (1,6,7,9). Clinically, WD often has two phases: initial arthritis/arthralgia, then (months to years later) abdominal pain, diarrhea, and weight loss (1-4,7,9,10). Other manifestations include fever, lymphadenopathy, pulmonary disease, endocarditis, encephalitis, bacteremia and neurological signs (cognitive impairment, ataxia, supranuclear ophthalmoplegia) (1,6,7). Laboratory tests usually show elevated inflammatory markers (1). Gastrointestinal findings include malabsorption, steatorrhea, malnutrition and muscle wasting (1,3,7).

Cardiac involvement can cause endocarditis, pericarditis, pleuritis, heart failure and has been reported with thrombosis and reversible pulmonary hypertension (PH). Post-mortem studies show cardiovascular involvement in >50% of cases (1,6,12). Initial diagnosis involves noninvasive PCR of stool/saliva samples, invasive biopsies (duodenal, lymph node, valve, CSF) and confirmed with Periodic acid-Schiff (PAS)-positive macrophages and villous atrophy (1,6). WD is treated with intravenous ceftriaxone or penicillin+streptomycin followed by trimethoprim–sulfamethoxazole for ≥12 months; therapy usually leads to rapid improvement, but relapses occur if eradication is inadequate (5-7). Untreated WD is fatal; nutritional support often resolves malnutrition within 2–3 months, although prolonged or higher-dose antibiotics may be required for relapse or complicated organ involvement (5-7). Long-term follow-up is recommended to monitor recurrence and manage

residual neurological or cardiac sequelae (5-7). Early recognition significantly improves outcomes.

CASE REPORT

An 81-year-old man with hypertension, type 2 diabetes, hyperlipidemia, chronic lymphocytic leukemia and previous prostate cancer presented with progressive arthralgias, weight loss, anorexia and immobility. He had a noteworthy history of extensive travel, including a trip to South America four years ago, with frequent visits to Third World countries.

Eight months before admission he developed worsening malaise, productive cough, dyspnea, elevated inflammatory markers and abdominal lymphadenopathy, with intermittent abdominal pain, diarrhea and constipation. On admission (June 2023) he had dyspnea and left leg swelling.

Laboratory tests showed the following: elevated erythrocyte sedimentation rate of 56 mm/h, leukocytes of 19.5 ×109/L, C-reactive protein of 62 mg/L, high-sensitivity troponin of 396 ng/L, D-dimer of 17,243 µg/L, N-terminal-pro-B-type natriuretic peptide (NT-pro-BNP) of 12,385.2 ng/L, hemoglobin of 120 g/L, mild renal impairment and low iron, ferritin, folate and vitamin D. Electrocardiography showed sinus rhythm with right bundle branch block and atrial fibrillation. Venous ultrasound confirmed left iliofemoral deep vein thrombosis (DVT). Computed tomography angiography excluded pulmonary embolism but suggested PH and right pleural effusion. Initial antibiotics (amoxicillin/

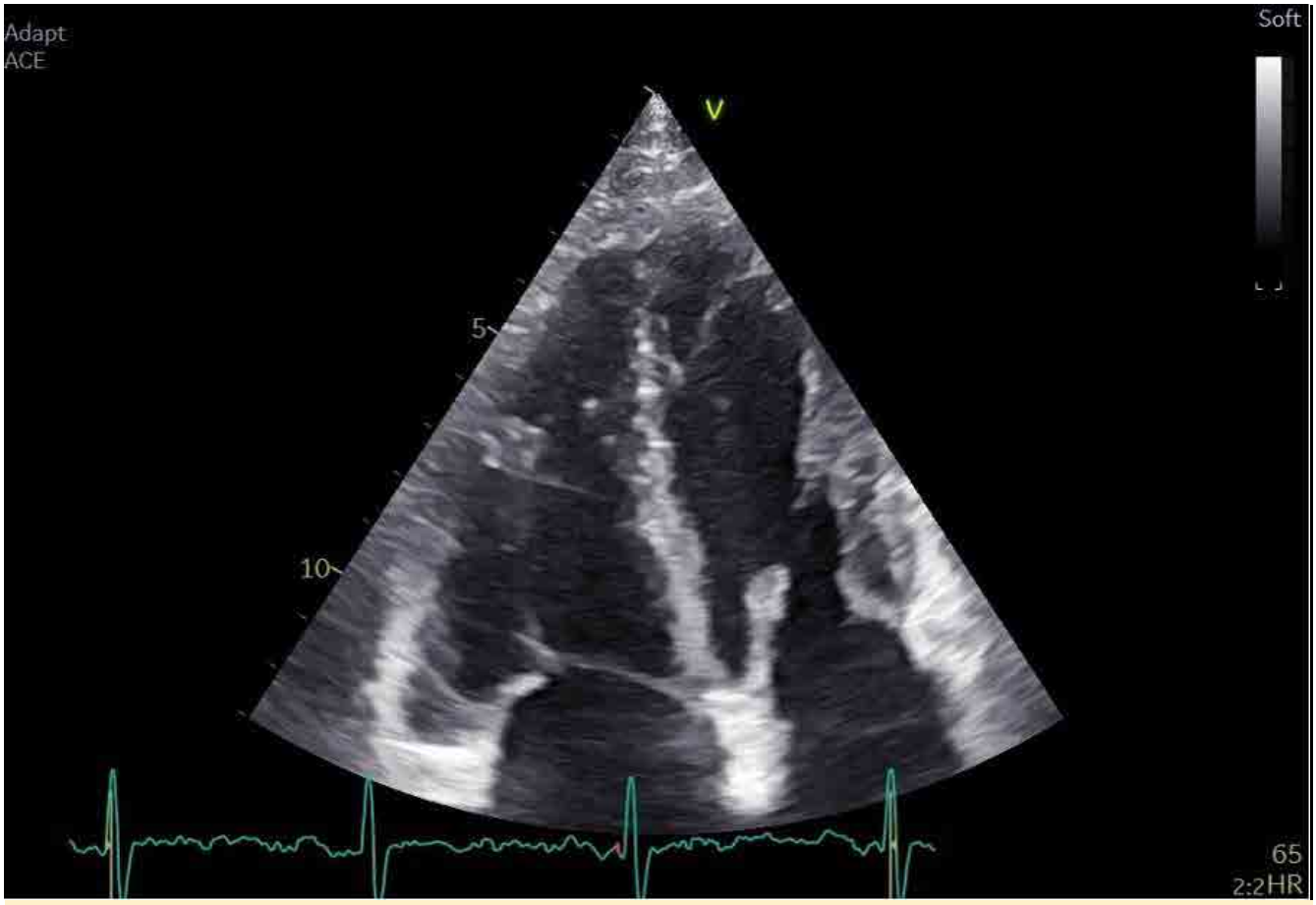

Figure 1. *Four-chamber view with enlarged right ventricle, slightly thickened free wall and weakened systolic function (RVEF 3D 41%, TAPSE 1.3 cm, FAC 29%) in the patient (J.B., 1941)*

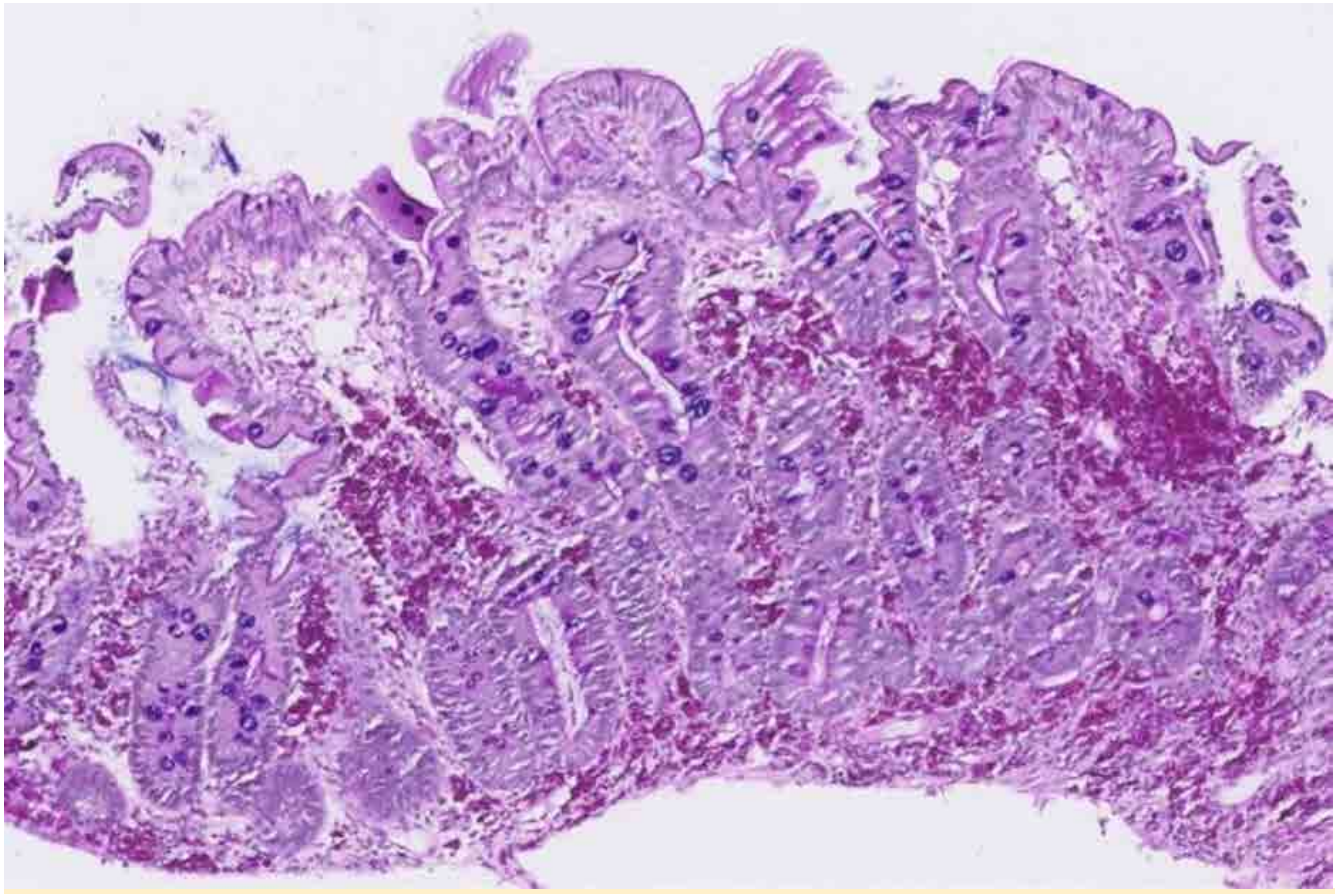

Figure 2. *Histology of duodenum mucosa with changes consistent with Whipple's disease in the patient (J.B.,1941): foamy macrophages are located in the lamina propria with villous atrophy.*

Table 1: *Comparison of laboratory findings on admission and at discharge*

	Laboratory values at admission	Laboratory values upon discharge
Leukocytes (x10^9/L)	19,5	14,5
Haemoglobin (g/L)	120	109
MCV (g/L)	80.5	82.1
Thrombocytes (10^9/L)	175	328
C-reactive protein (mg/L)	62	6
High-sensitivity troponin (ng/L)	396	/
D-dimer (ug/L)	17243	/
NT-pro-BNP (ng/L)	12385,2	803,5
BUN (mmol/L)	18,8	11.7
Creatinine (umol/L)	134	70

clavulanic acid, azithromycin) did not improve the patient's inflammation. Infection and tumor screens were negative. After a fall revealed ischemic infarction, anticoagulation was initially contraindicated; a vena cava filter was placed and low-molecular weight heparin was started once anticoagulation was deemed safe.

Echocardiography demonstrated right ventricular strain, mildly enlarged right ventricle (RV) with reduced systolic function (RV ejection fraction (RVEF) 41%, tricuspid annular plane systolic excursion (TAPSE) 1.3 cm, fractional area change (FAC) 29%, and moderate probable precapillary PH (systolic pulmonary artery pressure (sPAP) 56 mmHg.

Pleural fluid, stool and saliva PCR were positive for Tropheryma whipplei; duodenal biopsy confirmed Whipple's disease (Figure 2).

The patient received intravenous ceftriaxone 2 g/day for 19 days, the vena cava filter was removed, and anticoagulation was switched to apixaban 5 mg twice daily. Physiotherapy improved mobility; and within ten days, the patient could walk with assistance.

On discharge, antibiotics were changed to doxycycline and hydroxychloroquine, and later adjusted to sulfamethoxazole–trimethoprim when available. Follow-up showed improved inflammatory markers and NT-pro-BNP (803.5 ng/L). Four months later the corrected QT interval was prolonged (488 ms), prompting a regimen change (Table 1).

Seven months later, echocardiography revealed persistent moderate PH (sPAP 52 mmHg, mean PAP 30 mmHg) and right ventricular dysfunction (TAPSE 2.1, FAC 29%). LVEF remained normal (LVEF 3D 65%), with moderate diastolic dysfunction. The precise cause of PH remained unclear, although Whipple's disease may have been a contributory factor.

CONCLUSION

Whipple's disease is an uncommon systemic infection with variable manifestations and often delayed diagnosis. Our patient had arthralgia followed by weight loss, malnutrition, abdominal symptoms, chronic inflammation, extensive iliofemoral DVT, and persistent PH without pulmonary embolism. DVT may reflect immobility, systemic inflammation, endothelial activation, and infection-related hypercoagulability. Despite hypertension and diabetes suggesting pre-existing diastolic dysfunction, PH persisted after successful antibiotic therapy, indicating possible pulmonary vascular remodeling, direct pulmonary Tropheryma whipplei involvement, or irreversible vascular change. Stroke was likely cardioembolic due to atrial fibrillation. Diagnosis relied on PCR of pleural fluid, stool, and saliva and duodenal biopsy with PAS-positive macrophages. Early antibiotic treatment (ceftriaxone followed by oral therapy) produced clinical recovery, improved mobility, and reduced inflammatory markers in our case. Whipple's disease, although rare, should be considered in patients with unexplained weight loss, malnutrition, arthralgia, chronic inflammation, and gastrointestinal symptoms. Cardiovascular presentations including DVT and PH can occur and require prompt recognition and prolonged antibiotic therapy.

REFERENCES

1. Dolmans RA, Boel CH, Lacle MM, Kusters JG. Clinical Manifestations, Treatment, and Diagnosis of Tropheryma whipplei Infections. Clin Microbiol Rev. 2017;30(2):529-55.
2. Lopes A, Santos AF, Alvarenga MJ, Mello E Silva A. Whipple's disease: a rare case of malabsorption. BMJ Case Rep. 2018;2018.
3. Turcan S, Tofan-Scutaru L, Istrate V, Tirbu V. Whipple's disease? A case report and discussion. Med Pharm Rep. 2021;94(Suppl No 1):S76-S8.
4. Berent R, Auer J, Lassnig E, von Duvillard SP, Crouse SF, Tuppy H, et al. Whipple's disease: misdiagnosed as sarcoidosis with further tricuspid valve endocarditis and pulmonary embolism - a case report. BMJ Case Rep. 2009;2009.
5. Cardoso J, Gomes L, Santos S, Moreira H, Gomes P, Rua J, et al. Whipple's Disease: A Rare Cause of Malabsorption Syndrome. GE Port J Gastroenterol. 2020;27(4):283-9.
6. Dutly F, Altwegg M. Whipple's disease and "Tropheryma whippelii". Clin Microbiol Rev. 2001;14(3):561-83.
7. Kutlu O, Erhan S, Gökden Y, Kandemir Ö, Tükek T. Whipple's Disease: A Case Report. Med Princ Pract. 2020;29(1):90-3.
8. Biagi F, Balduzzi D, Delvino P, Schiepatti A, Klersy C, Corazza GR. Prevalence of Whipple's disease in north-western Italy. Eur J Clin Microbiol Infect Dis. 2015;34(7):1347-8.
9. Batista M, Santos ML, Silva C, Pereira G, Alves G, Cotter J. Whipple's Disease: A Case Report. Cureus. 2023;15(6):e39963.
10. Aguiar Ferreira A, Gomes P, Curvo-Semedo L, Donato P. Whipple's disease: imaging contribution for a challenging case. BMJ Case Rep. 2020;13(2).
11. Seddon O, Hettiarachchi I. Whipple's endocarditis presenting as ulnar artery aneurysm; if you don't look, you won't find. BMJ Case Rep. 2017;2017.
12. Terrones-Peinador M, Eremiev-Eremiev S, Pigrau-Serrallach C, Solans-Laque R. Recurrent thrombosis as a clinical presentation of Whipple disease. BMJ Case Rep. 2022;15(2).