Morfološka raznolikost zgornjih centralnih stalnih sekalcev ter njihova povezava z zaznavanjem estetike, funkcije in samozavestjo

Different morphologic shapes of permanent maxillary central incisors and the association with aesthetics perception, self-reported function, and self-esteem

Avtor / Author

Maša Furjan [1], Anita Fekonja[1]

Ustanova / Institute

[1] Univerza v Mariboru, Medicinska fakulteta, Maribor, Slovenija

[1]University of Maribor, Faculty of Medicine, Maribor, Slovenia

Ključne besede:
zgornji centralni stalni sekalec, oblika krone, samopodoba, funkcija, estetika

Key words:
maxillary central incisors; crown shapes; self-esteem; function; aesthetics

Članek prispel / Received
14. 2. 2026
Članek sprejet / Accepted
19. 6. 2026

Naslov za dopisovanje / Correspondence
Assist. Prof. Anita Fekonja, DMD, PhD, University of Maribor, Faculty of Medicine
anita.fekonja1@um.si

Izvleček

Namen: *Namen raziskave je bil ugotoviti, katera morfološka oblika zgornjih stalnih centralnih sekalcev prevladuje v Podravski regiji Slovenije, ter tudi oceniti njen vpliv na estetiko, funkcijo in samozavest preiskovancev.*
Metode: *Analizirali smo 184 študijskih modelov, da bi določili najpogostejšo obliko krone zgornjih centralnih stalnih sekalcev. Poleg tega smo podatke zbrali s prilagojenim vprašalnikom, ki ga je izpolnilo 328 anketirancev. Podatke smo analizirali in vrednosti p < 0,05 smo šteli za statistično značilne.*
Rezultati: *Rezultati so pokazali, da je bila najpogostejša oblika krone zgornjih stalnih centralnih sekalcev trikotna (47,3 %); sledile so podolgovata (36,4 %), kvadratna (13,6 %) in ovalna oblika (2,7 %). Med spoloma ni bilo statistično značil-*

Abstract

Purpose: *The aim of the present study was to evaluate which morphologic shape of permanent maxillary central incisors predominates in the Podravska region of Slovenia and the association with aesthetic perception, self-reported function, and self-esteem.*
Methods: *A total of 184 study casts were analyzed to determine the crown shape of permanent maxillary central incisors. Data were also collected about the influence of crown shapes on aesthetics and function using a modified questionnaire, which was completed by 328 respondents. Data were analyzed and P-values < 0.05 were considered statistically significant.*
Results: *The most frequent maxillary central incisor crown shapes were triangular (46.7%), followed by elongated (35.9%), square (14.1%), and ovoid (3.3%) without a statistically signifi-*

https://doi.org/10.18690/actabiomed.307, CC BY 4.0
© 2026 Avtor(ji) / The Author(s)

nih razlik. Podolgovata oblika zgornjega centralnega stalnega sekalca je bila med vsemi štirimi morfološkimi oblikami ocenjena kot estetsko najbolj privlačna. Večina udeležencev (99,1 %) je menila, da imajo zobje vpliv na samopodobo. 190 (57,9 %) preiskovancev je bilo v ortodontski obravnavi, pri čemer se jih je 46 % za zdravljenje odločilo zaradi okrnjene estetike in funkcije. Večina anketirancev (93,9 %) je zanikala težave z izraščanjem zgornjih centralnih sekalcev v otroštvu. Deset (3 %) udeležencev je imelo govorne motnje zaradi nepravilnega položaja zgornjih centralnih sekalcev, od tega jih je šest obiskovalo logopeda. Križni griz je bil med ponujenimi možnostmi najmanj estetski položaj sekalcev, pri čemer je bila razlika statistično značilna.

Zaključki: *Razumevanje morfologije zgornjih stalnih centralnih sekalcev lahko prispeva k uspešnejši obravnavi na področju restavrativnega zobozdravstva, ortodontije in protetike ter doprinese k izboljšanju videza zob, njihove funkcije in estetske podobe obraza.*

cant difference between sexes. The elongated maxillary central incisor ranked the most liked out of all four morphologic shapes. Most of the participants (99.1 %) believed that teeth have an impact on self-esteem. Overall, 190 (57.9%) participants had undergone orthodontic treatment, 46% of who were due to compromised aesthetics and function. Most of the respondents (93.9%) denied having problems with maxillary central incisor eruption during childhood. Ten (3%) participants had speech disorders due to the incorrect position of the maxillary central incisors, six of who were required to see a speech therapist. The crossbite was the least liked position of the incisor among the selected options with a statistically significant difference (p = 0.001).

Conclusions: *Understanding the morphology of permanent maxillary central incisors is important for pediatric and restorative dentistry. For orthodontists who provide optimal treatment planning, understanding the morphology of permanent maxillary central incisors may be useful to achieve improved dental appearance, function, and facial aesthetic.*

INTRODUCTION

The maxillary central incisor is positioned along the median plane, making the maxillary central incisor the most visible tooth, and as a result the maxillary central incisor has a key role in facial and smile aesthetics (1). The maxillary central incisor erupts, on average, between 7 and 8 years of age (1, 2) and root development is completed by 10 years of age (1). When a primary tooth is lost, the permanent tooth is at the eruption point and in the proper position to replace its predecessor (1,3). There may be delays in the eruption of the permanent maxillary central incisor due to various factors (4-6).

The shape of the permanent maxillary central incisor varies, often reflecting the shape of the face (7, 8). Some researchers have reported that tooth size and shape vary based on ethnicity, sex, and dietary habits (9). Indeed, some researchers have even identified differences among individuals of the same ethnicity (10-12). Williams classified maxillary central incisor dental crowns into three basic shapes: square; ovoid; and triangular (13). Over the ensuing years, various classifications of maxillary central incisor dental crowns have been reported (14). One of the maxillary central incisor dental crowns was developed by Gašperšič et al. (7), who added an elongated shape to the Williams classification.

The chisel-shaped form of incisors has a crucial role in functions, such as cutting or tearing food, supporting the lips, and facilitating speech [voice formation] (7, 15). The absence of a permanent maxillary central incisor significantly affects facial aesthetics as well as function, speech, and psychological well-being due to the specific location of the incisor (16-19). When a speech error is identified alongside a morphologic dental irregularity, further treatment involving a speech therapist and an orthodontist is required (20, 21). Dental developmental anomalies, such as a palatal pit, palatocervical groove, and talon cusp, can

be present in the maxillary central incisor (1, 22-26). The permanent maxillary central incisor has an important role in aesthetics and function, as well as phonetics and psychosocial well-being. Therefore, the aim of this study was to determine which morphologic shape of the maxillary central incisor predominates in the Podravska region of Slovenia, as well as the potential impact of dental appearance on self-esteem. In addition, we determined whether individuals had undergone orthodontic treatment, and if so, the reasons for orthodontic treatment. Furthermore, we were also interested in understanding individual's aesthetic perception regarding various morphologic shapes of the permanent maxillary central incisor as well as different positions of the permanent maxillary central incisor in the dental arch. Furthermore, we determined whether individuals had experienced issues with eruption of the permanent maxillary central incisors, speech difficulties, or had visited a speech therapist.

MATERIALS AND METHODS

The present study was reviewed and approved by the Institutional Review Board of Community Healthcare Centre Maribor (No. 02/010/03-12/01/24) and conducted between 1 October 2023 and 20 October 2025 in accordance with the Declaration of Helsinki at the Orthodontic Department of Community Healthcare Centre Maribor. The material for the present study included records collected by examining consecutive study casts and using a modified questionnaire (Table 1).

Study casts

The study casts of 200 patients who were treated in the Orthodontic Department of the Community Healthcare Centre were reviewed. Study casts were consecutively selected based on the availability of records and fulfillment of inclusion criteria. The inclusion criteria were fully erupted permanent central incisors and high-quality study casts that allowed for determining the shape of the maxillary central incisors. The exclusion criteria were anomalies in the oral cavity (for example, hypodontia, cleft lip/palate, or any syndrome) that could affect the shape and size of the maxillary central incisor, fillings (restorations), and enamel striping or abrasion, as well as impacted or previous loss of a maxillary central incisor due to trauma, caries, or periodontal disease. Of these 200 study casts, five were excluded because of poor quality, 10 were excluded because the first maxillary central incisors were not fully erupted, and one was excluded because of maxillary lateral incisor hypodontia. Thus, a total of 184 study cases were included in the current study (Figure 1).

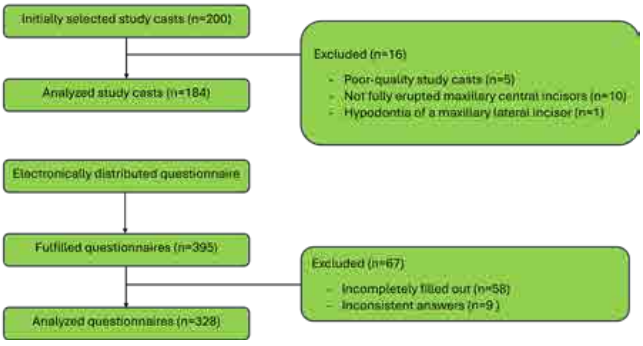

Figure 1. *Flow chart.*

The crown shapes of the maxillary central incisors were classified as square, elongated, ovoid, and triangular by a single examiner (Figure 2). Prior to analysis, the examiner re-evaluated 30 randomly selected study casts after a 2-week interval.

A square maxillary central incisor (Figure 2a) has nearly parallel mesial proximal surfaces with a mesio-incisal angle that is an approximate right angle. Both maxillary central incisors have a proximal contact surface which is longer by one-half the length of the crown. The cervical line is wide and shaped like the letter 'U'. The incisal edge is straight and has a wider mesiodistal distance than the ovoid shape. The width and length of the crown are similar.

An elongated maxillary central incisor (Figure 2b) appears similar to the square shape, except the proximal surfaces are longer.

An ovoid maxillary central incisor (Figure 2c) has

Table 1. *Modified questionnaire*

Question	Answer
1. Gender Please mark one variable	
male	
female	
2. Age Please mark one variable	
20 – 30 years	
30 – 40 years	
40 – 50 years	
50 – 60 years	
3. Status Please mark one variable	
Students of dental/general medicine	
Professionals in dentistry	
Laypersons	
4. What's your opinion about central incisors shape? Answers were given on a 4-point visual analogue scale (VAS) ranging: 1 (most liked), 2 (more like), 3 (liked), 4 (least liked). Please mark one grade on the scale	
square	
elongated	
ovoid	
triangular	
5. Do you think teeth play a role in a person's self – esteem? Please mark one variable	
Yes	
No	
6. Have you ever been in orthodontic treatment? Please mark one variable	
Yes	
No	
No, but I would want to.	
If you answered yes, what was the reason? Please mark one variable	
Compromised aesthetics (positional irregularities of teeth)	
Incorrect bite	
Compromised function	
I do not remember	
7. Question for dentists: What is the most common reason to referring patient to an orthodontist? Please mark one variable	
Positional irregularities of teeth	
Incorrect bite	
Compromised function	
At the request of parents	
8. What is your opinion on different teeth positions? Answers were given on a 4-point visual analogue scale (VAS) ranging 1 (most liked), 2 (more like), 3 (liked), 4 (least liked) Please mark one grade on the scale	
crowding	
diastema mediana	
cross bite	
spacing	
9. Did you have any issues with the eruption of permanent upper central incisors during childhood?	
Yes	
No	
10. Did you have any problems with speech due to incorrect position of incisors?	
Yes	
No	
11. If you answered yes, did you visit a speech therapist? **Please mark one variable**	
Yes	
No	

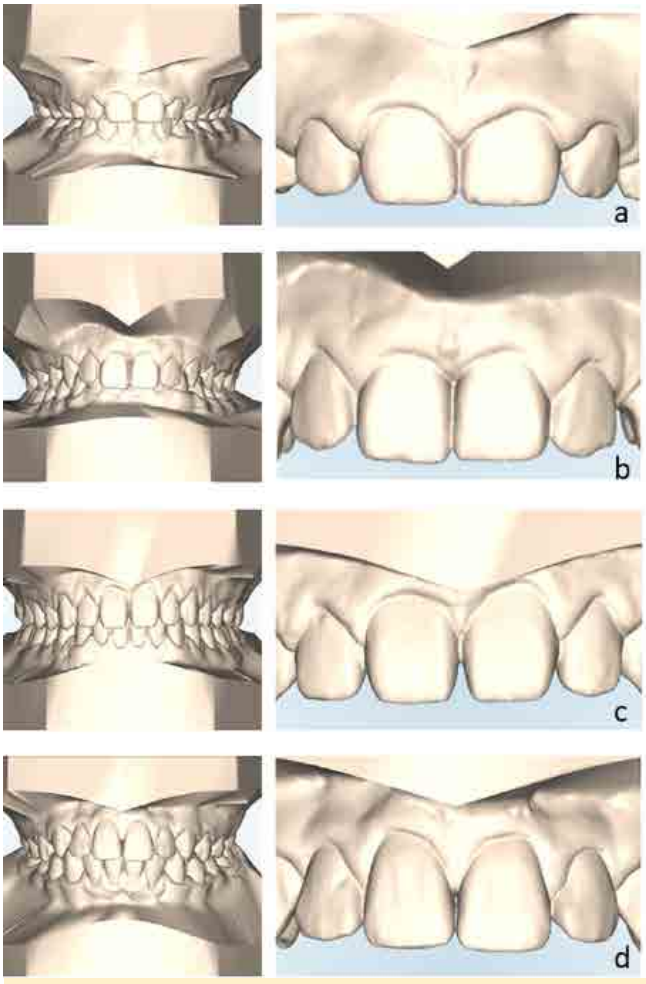

Figure 2. *Various crown morphologies evaluated as square (a), elongated (b), ovoid (c), and triangular (d).*

rounded mesial and distal proximal surfaces. The proximal contact surface is short and in the middle of the proximal surface. Therefore, a triangle usually appears below the contact of the two central incisors. The cervical line is shaped like the letter 'U', which is like the square-shaped maxillary central incisor but more ovoid.

A triangular maxillary central incisor (Figure 2d) has mesial and distal proximal surfaces that converge cervically. The proximal contact surface of both maxillary central incisors is approximately one-half the length of the crown near the incisal edge. Therefore, the interdental papilla is located more incisal than the other shapes. The cervical line is shorter than the incisal edge and slightly V-shaped. The mesial and distal incisal angles are slightly sharp.

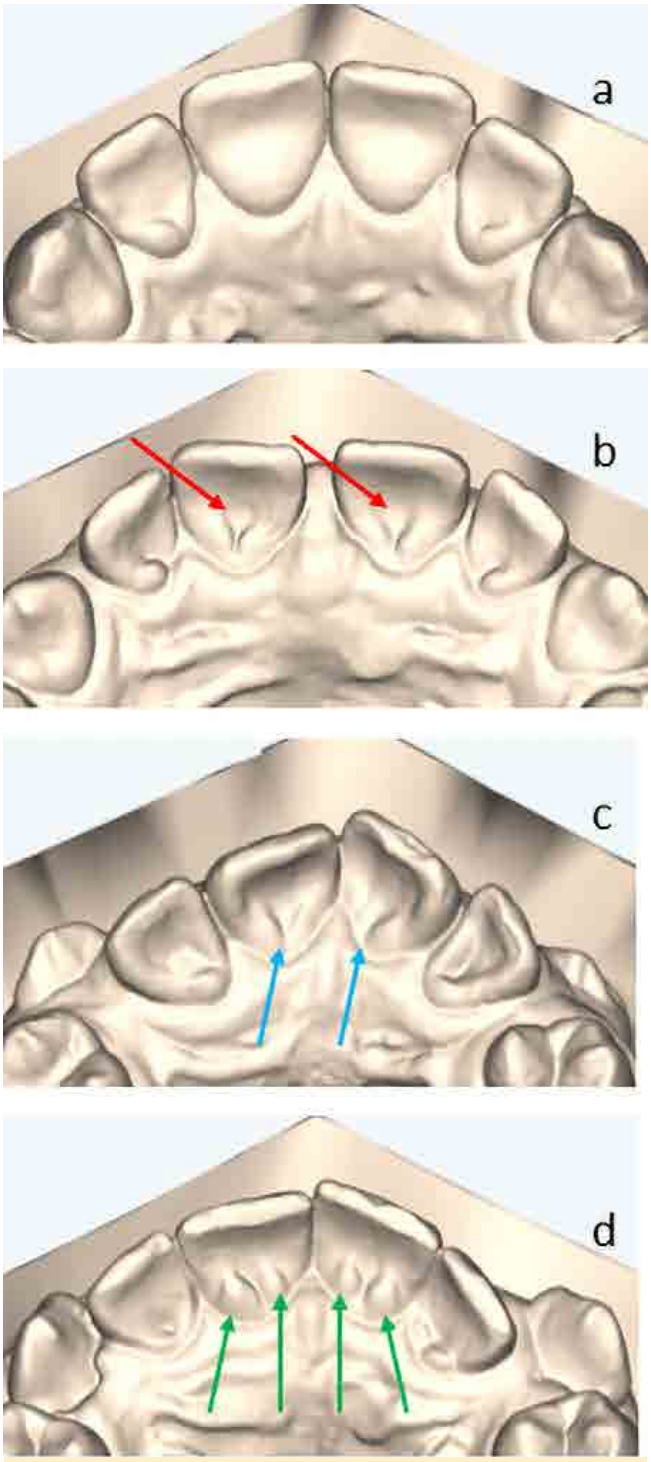

Figure 3. *Normal palatal surface (a), palatal pit [red arrows (b)], palatocervical groove [blue arrows (c)], and palatal tubercule [green arrows (d)].*

We also analyzed palatal surface as normal (Figure 3a) with a palatal pit, palatocervical grove, and double palatal tubercules. The palatal pit (Figure 3b) is

situated in the deep palatal fossa on the incisal surface of the cingulum. The palatocervical grove (Figure 3c) extends from the palatal pit, across the cingulum, and may extend up on the root. Double palatal tubercules (Figure 3d) extend in the cingulum area.

Modified questionnaire

Data on the aesthetic perception of different permanent maxillary central incisor shapes, as well as the potential impact of dental appearance on an individual's self-esteem, problems with maxillary central incisor eruption and possible orthodontic treatment were collected through the use of a modified questionnaire. The modified questionnaire was developed based on previously published studies (15) and adapted for the purposes of the current study. The questionnaire was distributed electronically across Slovenia via social media platforms (e.g., Facebook), e-mail, and WhatsApp. Participants were recruited using a convenience sampling method among three study groups in Slovenia, as follows: dental/general medicine students; professionals working in the field of dentistry; and laypersons. Laypersons were defined as individuals without formal dental education and were invited through general online networks. A total of 395 respondents completed the questionnaire, of whom 67 were excluded due to incomplete or inconsistent responses (Figure 1). Therefore, although the study casts originated from the Podravska region, the questionnaire sample represents a wider Slovenian population. A flowchart illustrating the study sample is presented in Figure 1.

Statistical Analysis

Intra-examiner reliability was assessed using a paired t-test. The recorded data were entered into a spread sheet in Microsoft Office Excel 2007. Descriptive statistics were expressed as frequencies and percentages for categorical variables, while ordinal variables obtained from the visual analogue scale were summarized as medians and interquartile ranges. The association between categorical variables was analyzed using a chi-square (χ^2) test of independence. Fisher's exact test was applied in cases in which the expected frequencies were < 5. Visual analogue scale score comparisons between the two independent groups were performed using the Mann-Whitney U test, whereas comparisons among three independent groups were analyzed using the Kruskal-Wallis test. The significance level was set at a $P < 0.05$.

RESULTS

Study casts

Intra-examiner reliability analysis showed no statistically significant difference detected in the crown shape. Of the 200 examined study casts, 184 fulfilled the selection criteria (Table 2). Of the 184 study casts, 87 were from males (47.3 %) and 97 were from females (52.7 %). The distribution of different maxillary central incisor crown shapes according to sex is presented in Table 2. The triangular shape was most frequent (47.3 %), followed by elongated (36.4 %), square (13.6 %), and ovoid shapes (2.7 %) in both sexes. There was no statistically significant association between crown shape distribution and sex (x2 = 3.37, P = 0.338).

Table 3 presents the distribution of different palatal structures according to sex. There was no statistically significant association between different palatal structures and sex (Fisher's exact test, P = 0.850).

Table 2. *The distribution of different crown shapes of permanent maxillary central incisors by sex.*

Shape / Sex	Square n (%)	Elongated n (%)	Ovoid n (%)	Triangular n (%)	Total n (%)
Male	24 (6.5)	62 (16.8)	2 (0.5)	86 (23.4)	174 (47.3)
Female	26 (7.1)	72 (19.6)	8 (2.2)	88 (23.9)	194 (52.7)
Total	50 (13.6)	134 (36.4)	10 (2.7)	174 (47.3)	368 (100)

Table 3. *The distribution of different structures on palatal surface by sex.*

Patatal structures / Gender	Palatal pit n (5)	Palatocervical groove n (%)	Double palatal cusp n (%)	Total n (%)
Male	4 (1.1)	3 (0.8)	1 (0.3)	8 (2.2)
Female	5 (1.4)	3 (0.8)	3 (0.8)	11 (3.0)
Total	9 (2.5)	6 (1.6)	4 (1.1)	19 (5.2)

Table 4. *The distribution of status (profession), sex, and age (years) of the study participants.*

Status	Age / Sex	20 – 30 n (%)	30 – 40 n (%)	40 – 50 n (%)	50 – 60 n (%)	total n (%)
Students	M	31 (9.4)	0 (0)	0 (0)	0 (0)	31 (9.4)
	F	100 (30.5)	0 (0)	0 (0)	0 (0)	100 (30.5)
Professionals in dentistry	M	1 (0.3)	13 (4.0)	9 (2.7)	8 (2.4)	31 (9.4)
	F	10 (3.0)	53 (16.2)	28 (8.5)	26 (8.0)	117 (35.7)
Laypersons	M	16 (4.9)	1 (0.3)	0 (0)	0 (0)	17 (5.2)
	F	20 (6.2)	5 (1.5)	4 (1.2)	3 (0.9)	32 (9.8)
Total		178 (54.3)	72 (21.9)	41 (12.5)	37 (11.3)	328 (100)

Legend: M: male; F: female.

Modified questionnaire

A total of 395 respondents (participants) completed the modified questionnaire; 67 were excluded due to incomplete or inconsistent responses. The final sample consisted of 328 participants.

The distribution of participants by profession, sex, and age is presented in Table 4. No significant association was detected between sex and age distribution (χ^2 = 2.36, P = 0.50) or between sex and professional status (χ^2 = 3.62, P = 0.16). However, a significant association was detected between age and professional status (χ^2 = 268.4, P < 0.001).

Participants were asked to evaluate photographs of four different maxillary central incisor crown shapes using a 4-point VAS, ranging from 1 (most liked) to 4 (least liked). A significant difference existed with respect to the aesthetic perception of tooth shapes (H = 312.5, P < 0.001) with elongated shape most liked and square shape least liked (Table 5). Subgroup analyses according to professional status and sex are presented in Table 6. Square crown shape received the lowest aesthetic evaluations overall. Statistically

Table 5. *The survey respondents' evaluations of the different maxillary central incisor crown shapes.*

Shape	median	IQR
Square	4	3-4
Elongated	2	1-2
Ovoid	3	2-3
Triangular	3	2-3

Legend: IQR: interquartile range

Answers were given on a four-point visual analogue scale (VAS) ranging from 1 (most liked) to 2 (more liked), 3 (liked), and 4 (least liked).

Table 6. *The survey respondents' evaluations of the different maxillary central incisor*

		Shape evaluation on VAS	
Status	**Sex**	**mediana**	**IQR**
Square shape			
Students	M	3	3-4
	F	4	3-4
Professionals in dentistry	M	4	3-4
	F	4	4-4
Laypersons	M	3	2-4
	F	3	1-4
Elongated shape			
Students	M	2	1-2
	F	1	1-2
Professionals in dentistry	M	2	1-3
	F	2	1-2
Laypersons	M	2	1-3
	F	2	1-2
Ovoid shape			
Students	M	2	1-3
	Ž	2	2-3
Professionals in dentistry	M	2	2-3
	Ž	3	2-3
Laypersons	M	2	1-3
	Ž	3	2-3
Triangular shape			
Students	M	3	2-4
	Ž	3	2-3
Professionals in dentistry	M	2	1-3
	Ž	2	1-3
Laypersons	M	3	2-3
	Ž	3	2-4

Legend: M: male, F: female, IQR: interquartile range

Answers were given on a four-point visual analogue scale (VAS) ranging from 1 (most liked) to 2 (more liked), 3 (liked), and 4 (least liked).

significant differences among students, professionals in dentistry, and laypersons were detected for square crown shape evaluations (H = 18.72, P < 0.001). Significant sex-related differences were also identified (U = 8373.5, P = 0.017). Elongated crown shape evaluations differed significantly among the examined groups (H = 6.21, P = 0.045), as well as between males and females (U = 11674.5, P = 0.006). No statistically significant differences were detected for ovoid crown shape among the examined groups (H = 2.08, P = 0.353) or between sexes (U = 8622.0, P = 0.082). Triangular crown shape evaluations revealed statistically significant differences among students, professionals in dentistry, and laypersons (H = 6.12, P = 0.047). However, no statistically significant sex differences were detected with respect to triangular crown shape (U = 10169.0, P = 0.638).

Almost all participants (99.1 %) reported that teeth have a role in self-esteem, while only three respondents indicated that teeth have no role in self-esteem.

A total of 190 (57.9 %) participants reported having undergone orthodontic treatment (Table 7). A statistically significant association was detected between sex and orthodontic treatment (χ^2 = 6.05, P = 0.048), indicating that females reported orthodontic treatment more frequently than males Compromised aesthetics and function were the most common reason for orthodontic treatment (46%), followed by aesthetic reasons (34%) and impaired function (13%). A small proportion of participants (7%) could not recall the indication for orthodontic treatment. No statistically significant difference was detected for orthodontic treatment between sexes (χ^2 = 5.63, P = 0.131).

Twenty respondents (6.1%) reported problems with eruption of the maxillary central incisors in childhood. No statistically significant difference was detected with respect to childhood eruption of the maxillary central incisors according to participant status (χ^2 = 0.25, P = 0.883) or sex (χ^2 = 1.39, P = 0.239). Ten (3%) respondents reported speech disorders associated with the position of the maxillary central incisors and six required speech therapy.

Of 136 dentists, 78 (57.3 %) acknowledged that the most frequent indication for referring patients to an orthodontist is an incorrect bite (Table 8).

Participants also evaluated different positions of

Table 7. *Results of the question regarding whether the participants underwent orthodontic treatment.*

Status	Sex	Yes n (%)	No n (%)	No, but I would want to be. n (%)	Total n (%)
Students	M	16 (51.6)	12 (38.7)	3 (2.1)	31 (100)
	F	73 (73.0)	22 (22.0)	5 (5.0)	100 (100)
Professionals in dentistry	M	16 (51.6)	12 (38.7)	3 (9.7)	31 (100)
	F	63 (53.8)	47 (40.2)	7 (6.0)	117 (100)
Laypersons	M	5 (29.4)	8 (47.1)	4 (23.5)	17 (100)
	F	17 (53.1)	10 (31.3)	5 (15.6)	32 (100)
Total		190 (57.9)	111 (33.9)	27 (8.2)	328 (100)

Legend: M: male, F: female

Table 8. *The survey respondents' responses to the question regarding the most common reason for referral to an orthodontist.*

Question for dentists: What is the most common reason for referring a patient to an orthodontist?	Results n (%)
Positional irregularities of teeth	41 (30.2)
Incorrect bite	78 (57.3)
Compromised function	12 (8.8)
At the request of parents	5 (3.7)
Total	136 (100)

maxillary central incisors in the dental arch to rank photographs from 1 (most liked) to 4 (least liked). The results are presented in Table 9. Significant differences in aesthetic preference among tooth positions were detected ($H = 340.2$, $P < 0.001$) with crossbite rated least favorably (77.4% selected a rating of 4).

Table 9. *The survey respondents' evaluations of different maxillary central incisor crown positions.*

Teeth position	median	IQR
Crowding	2	2-3
Diastema mediana	3	2-3
Crossbite	4	4-4
Spacing	1	1-1

Legend: IQR: interquartile range

Answers were given on a four-point visual analogue scale (VAS) ranging from 1 (most liked) to 2 (more liked), 3 (liked), and 4 (least liked).

DISCUSSION

The concept of beauty comprises symmetry and harmony, which is expressed through the proportional relationship of the face and teeth. Oral conditions can greatly affect the psychological, social, and functional health of patients. The most visible teeth when smiling are the maxillary central incisors (27). Incisor shape is important in orthodontics for achieving proper tooth contact and intercuspation. For example, an ovoid shape often requires striping of the proximal surface to achieve good proximal contact. The shape of the maxillary central incisor is also of great importance in restorative dentistry and prosthodontics for the aesthetic appearance of a smile.

Although maxillary central incisors shapes have been studied in various ethnic groups over the years (13,

26, 27), no published study has addressed which shape predominates in the Slovenian population. However, one study examined the relationship between the length and width of the face and the length and width of the crown of the maxillary central incisor (8) and another study investigated the frequency of different crown shapes of permanent maxillary lateral incisors (28). In the present study the predominant shape of the permanent maxillary central incisor is triangular (47.3 %), followed by elongated (36.4 %), square (13.6 %), and ovoid (2.7 %). Differences are apparent when comparing the results of the present study with other studies (26, 27). Paranhos et al. [26] reported that the ovoid shape was most common and the triangular shape was least common, which is in contrast to our results. Trigo-Humaran et al. (27) reported that the ovoid shape was least common, which is consistent with the findings in the current study but the square shape was most common, which differs from the results herein. However, if the square and elongated maxillary central incisor shapes were evaluated together in the current study, the results would have been completely aligned with the findings reported by Trigo-Humaran et al. (27). It should be noted that methodologic differences between studies may have influenced the results. Specifically, some studies relied on visual assessment, while other studies used standardized measurements or digital analysis. These methodologic variations limit direct comparability between findings.

Palatal structures, such as a palatal pit and palato-cervical groove, allow plaque accommodation and can lead to caries and periodontal disease (24, 25). A palatal pit may be located between the cingulum and palatal fossa and may be located near the center of the palatocervical groove if that structure is present. These dental anomalies occurred in 2.5 % and 1.5 % of study casts in the present study, respectively. This finding is agreement with a previous study (24). The palatal pit and palatocervical groove more frequently occur in maxillary lateral incisors than maxillary central incisors (1,24, 28).

The extended palatal tubercule has a greater predilection for the maxilla and when located in the cingulum area is associated with occlusal interferences and disharmony (23,25,28, 29). The prevalence of an extended palatal tubercule in the cingulum area was 1.1 % of maxillary central incisors in the present study. This finding is consistent with the results reported by Guven et al. (25). In the literature, we found that the prevalence of an extended palatal tubercule according to the extant literature is less frequent in the maxillary central incisor than the maxillary lateral incisors (22,23,26,28).

The aesthetic appearance of a smile is strongly influenced by the shape, position, and color of the permanent maxillary central incisors (30). The maxillary anterior teeth are the most important factor in achieving an aesthetic smile and crown shape ranks highest of all the various features that contribute to overall attractiveness, as highlighted by Ong et al. (31). Generally, women exhibit rounder and softer tooth forms compared to men, whose teeth are perceived as angular and square, which harmonizes with appearance (3). Heravi et al. (32) reported that the crown shape of the incisors is the main factor influencing aesthetic preferences. Both males and females rated ovoid incisors as the most aesthetic, which is in contrast with the findings in the present study (i.e., elongated maxillary central incisors were rated most aesthetic). Heravi et al. (32) also reported that square-shaped maxillary central incisors are the least aesthetic, which is consistent with the findings in the current study. The aesthetic perception of maxillary central incisors is very important in restorative dentistry, prosthodontic, and orthodontic treatment. Even laypeople can identify characteristics of facial beauty. Anderson et al. (33) reported that dental professionals (orthodontists and restorative dentists) and laypeople share similarities and exhibit differences when considering aesthetic preference in maxillary central incisor shape. Although there was no consensus in preference among laypeople as a group, the preferences differed from orthodontists and restorative dentists. The position of maxillary incisors is also one of the most important factors that people notice when evaluating a smile (34). In the current study the crossbite position was rated as least aesthetic among the examined positions. In the present study tooth color was not evaluated.

Maxillary central incisors were shown to have a significant impact on self-esteem, which is consistent with the results of previous studies (35-37). Badran (35) reported that students who underwent orthodontic treatment had higher self-esteem than students who had not undergone orthodontic treatment, which is consistent with our findings, in which 57.9 % of the study participants had undergone orthodontic treatment and confirmed higher self-esteem.

Hall et al. (38) reported that 75% of the general dentists in the midwestern United States think that patient satisfaction is as important as functional/occlusal results. Di Blasio et al. (39) reported that the most common reason for referring a patient to an orthodontist is dental irregularities as an aesthetic problem. However, in the current study the most common reason was an incorrect bite.

Tuncer et al. (40) reported that the main reason for orthodontic treatment is to achieve better alignment of the teeth and dental aesthetics, while Coyne et al. (41) reported that the functional aspect is more important than aesthetics. Tuominen and Tuominen (42) reported that the main reasons for seeking orthodontic treatment are to improve dental aesthetics and correct occlusion, which agrees with the present study.

Absence or unerupted maxillary central incisors affect occlusion development (6) and smile and facial aesthetics (5, 43), as well as a child's psychological well-being (6). Tan et al. (44) and Aldowsari et al. (45) reported that 1.4% and 3% of maxillary central incisors had delayed eruption, respectively. The incidence of maxillary central incisor impaction was 0.1% in a previous study involving impacted teeth in the Slovenian population (5). In the present study 6% of the participants reported problems with maxillary central incisor eruption. The percentage in the present study was higher because this study included patients who were treated by an orthodontist and had a higher incidence of dental irregularities than the general population.

The production of the /s/ sound is influenced by the position of the maxillary incisors and some irregularities in incisor position may lead to pronunciation disorders (46). Several studies have addressed speech problems associated with missing anterior teeth (17, 47). Riekman et al. (16) reported that the premature loss of all primary maxillary incisors generally did not impact long-term speech development in most children tested between 5.4 and 11.5 years of age. In the present study adolescent respondents reported speech problems due to malposition of the maxillary central incisors, six of who were required to visit a speech therapist. Specific speech difficulties due to tooth positions were not evaluated in our questionnaire. It should be emphasized that the findings related to function and self-esteem are based on self-reported perceptions rather than objective clinical or psychological assessments.

The current study had limitations. Because study casts were from patients treated in an orthodontist in the Podravska region, the findings cannot be generalized to the entire Slovenian population. Although this study may not represent the entire Slovenian population, the results are useful. To obtain a more comprehensive understanding and ensure broader validation, future research should consider expanding this study to include multiple clinics, both in Maribor and other regions across Slovenia. It would also be important to obtain more information on the function of maxillary incisors in speech and the participation of a speech therapist.

The questionnaire, which included specific questions related to dentistry, was a limitation that could easily confuse laypeople with limited knowledge of dentistry.

CONCLUSIONS

The findings regarding the morphology of permanent maxillary central incisors are important to the field of restorative dentistry, prosthodontics, and orthodontics. Such findings can assist in achieving more effective treatment and can contribute to obtaining an improved dental appearance, function, and facial aesthetic.

REFERENCES

1. Bath Balogh M, Fehrenbach MJ. Dental Embryology, Histology, and Anatomy, 2nd ed.; Elsevier: St. Louis, MO, USA, 1997: 209-13.
2. Fekonja A. Evaluation of the eruption of permanent teeth and their association with malocclusion. Clin Exp Den. Res. 2022; 8: 836-42.
3. Nelson SJ, Ash MM Jr. Wheeler's Dental Anatomy, Physiology and Occlusion, 9th ed.; Elsevier: St. Louis, MO, USA, 2010.
4. Manuja N, Nagpal R. Delayed eruption of maxillary permanent central incisors due to bilateral tuberculate supernumerary teeth: Case report. J Dent Child. 2010; 77: 106-10.
5. Fekonja A. Radiographic characteristics of impacted teeth. AMB. 2015; 8: 18-26,
6. Seehra J, Yaqoob O, Patel S, O'Neill J, Bryant C, Noar J, Morris D, Cobourne MT. National clinical guidelines for the management of unerupted maxillary incisors in children. Br Dent J. 2018; 224: 779-85.
7. Gašperšič D, Cvetko E, Potočnik I, Fidler A. Anatomija zob; Medicinska fakulteta: Ljubljana, Slovenia, 2002: 19-22.
8. Dervarič T, Fekonja A. The relationship between the length/width of the face and the length/width of the crown of the permanent upper central incisors. J Clin Med. 2024; 13: 4698.
9. Olsson M, Lindhe J. Periodontal characteristics in individuals with varying form of the upper central incisors. J Clin Periodontol. 1991;18: 78-82.
10. Lavelle CL. Maxillary and mandibular tooth size in different racial groups and in different occlusal categories. Am J Orthod. 1972; 61: 29-37.
11. Doris JM, Bernard BW, Kuftinec MM, Stom D. A biometric study of tooth size and dental crowding. Am J Orthod. 1981;79: 326-36.
12. Gillen RJ, Schwartz RS, Hilton TJ, Evans DB. An analysis of selected normative tooth proportions. Int J Prosthodont. 1994; 7: 410-17.
13. Williams JL. A New Classification of Human Tooth Forms with a Special Reference to a New System of Artificial Teeth, 1st ed.; The Dentisti Supply Co.: New York, NY, USA, 1914: 30-7.
14. Ibrahimagić L, Jerolimov V, Celebić A, Carek V, Baucić I, Zlatarić DK. Relationship between the face and the tooth form. Coll Antropol. 2001; 25: 619-26.
15. Fekonja A. Prevalence of dental developmental anomalies of permanent teeth in children and their influence on esthetics. J Esthet Restor Dent. 2017; 29: 276-83.
16. Riekman GA, el Badrawy HE. Effect of premature loss of primary maxillary incisors on speech. Pediatr Dent. 1985; 7: 119-22.
17. Bankson NW, Byrne MC. The relationship between missing teeth and selected consonant sounds. J Speech Lang Hear Disord. 1962; 27: 341-8.
18. Rodd HD, Barker C, Baker SR, Marshman Z, Robinson PG. Social judgements made by children in relation to visible incisor trauma. Dent Traumatol. 2010; 26: 2-8.
19. Mockutė G, Klimaitė G, Smailienė D. The Morphology of Impacted Maxillary Central Incisors: A Systematic Review. Medicina. 2022; 22: 462.
20. Farčnik F, Ovsenik M, Primožič J. Obravnava nepravilnosti orofacialnega področja s Franklovimi regulatorji funkcije; Zavod Orthos: Medicinska fakulteta: Ljubljana, 2014.
21. Levc, S. Liba laca lak: kako pomagamo otroku do boljšega govora; Ljubljana, 2014.
22. Guttal KS, Naikmasur VG, Bhargava P, Bathi RJ. Frequency of developmental dental anomalies in the Indian population. Eur J Dent. 2010; 4: 263-9.
23. Hattab FN, Yassin OM, al-Nimri KS. Talon cusp in permanent dentition associated with other dental anomalies: Review of literature and reports of seven cases. ASDC J Dent Child. 1996; 63: 368-76.

24. Gaudex Y, Gandillot V, Fontanille I, Bouchard P, Kerner S, Carra MC. Palatal groove associated with periodontal lesions: a systematic review illustrated by a decisional tree for management. BMC Oral Health. 2024; 24: 1037.
25. Guven Y, Kasimoglu Y, Tuna EB, Gencay K, Aktoren O. Prevalence and characteristics of talon cusps in Turkish population. Dent Res J. 2016; 13: 145-50.
26. Paranhos L, Jóias R, Velasco L, Bérzin F, Júnior E. Prevalence of the different maxillary central incisor shapes in individuals with natural normal occlusion. Braz J Oral Sci. 2010; 9: 104-7.
27. Trigo-Humaran MM, Agüero-Romero AB, Lespade M, García-Cuerva JM, Iglesias ME. Central incisors shape and proportions prevalence in Argentinian university students: by visual assessment and a new standardized method. Acta Odontol. Latinoam. 2021; 34: 113-8.
28. Fekonja A. Morphological diversity of permanent maxillary lateral incisors and their impact on aesthetics and function in orthodontically treated patients. Diagnostics 2022; 12: 2759.
29. Gündüz K, Celenk P. Survey of talon cusps in the permanent dentition of a Turkish population. J Contemp Dent Pract. 2008; 9: 84-91.
30. Rifkin R. Facial analysis: a comprehensive approach to treatment planning in aesthetic dentistry. Pract Periodontics Aesthet Dent. 2000; 12. 865-72.
31. Ong E, Brown RA, Richmond S. Peer assessment of dental attractiveness. Am J Orthod Dentofac Orthop. 2006; 130: 163-9.
32. Heravi F, Rashed R, Abachizadeh H. Esthetic preferences for the shape of anterior teeth in a posed smile. Am J Orthod Dentofac Orthop. 2011; 139: 806-14.
33. Anderson Anderson KM, Behrents RG, McKinney T, Buschang PH. Tooth shape preferences in an esthetic smile. Am J Orthod Dentofac Orthoped. 2005; 128: 458-65.
34. McKiernan EX, McKiernan F, Jones ML. Psychological profiles and motives of adults seeking orthodontic treatment. Int J Adult Orthodon Orthognath Surg. 1992; 7: 187-98.
35. Badran SA. The effect of malocclusion and self-perceived aesthetics on the self-esteem of a sample of Jordanian adolescents. Eur J Orthod. 2010; 32: 638-44.
36. Kaur P, Singh S, Mathur A, Makkar DK, Aggarwal VP, Batra M Sharma A, Goyal N. Impact of dental disorders and its influence on self-esteem levels among adolescents. J Clin Diagn Res. 2017; 11: ZC05-ZC08.
37. Amnaie A, Nasiri M, Adib M, Shirvani A. Relationship between self-concept and satisfaction with tooth alignment and demand for orthodontic treatment and professionally determined orthodontic needs. *J Isfahan Dent Sch.* 2012; 8: 1-9.
38. Hall JF, Sohn W, McNamara JA. Why do dentists refer to specific orthodontists? Angle Orthod. 2009; 79: 5-11.
39. Di Blasio M, Vaienti B, Pedrazzi G, Cassi D, Magnifico M, Meneghello S, Di Blasio A. Are the reasons why patients are referred for an orthodontic visit correct? Int J Environ Res Pub Health. 2021; 18: 5201.
40. Tuncer C, Canigur Bavbek N, Balos Tuncer B, Ayhan Bani A, Çelik B. How do patients and parents decide for orthodontic treatment—Effects of malocclusion, personal expectations, education and media. J Clin Pediatr Dent. 2015; 39: 392-9.
41. Coyne R, Woods M, Abrams R. The community and orthodontic care. Part II: Community-perceived importance of correcting various dentofacial anomalies. Part III: Community perception of the importance of orthodontic treatment. Aust Orthod J. 1999; 15: 289-301.
42. Tuominen ML, Tuominen RJ. Factors asso-

ciated with subjective need for orthodontic treatment among Finnish university applicants. Acta Odontol Scand. 1994; 52: 106-10.
43. Cons NC, Jenny J, Kohout FJ. DAI: The dental aesthetic index. Iowa City, Iowa: College of Dentistry, University of Iowa; 1986.
44. Tan C, Ekambaram M, Yiu CKY. Prevalence, characteristic features, and complications associated with the occurrence of unerupted permanent incisors. PLoS One 2018; 13: e0199501.
45. Aldowsari M, Alsaif FS, Alhussain MS, AlMeshary BN, Alosaimi NS, Aldhubayb SM, AlQahtani S. Prevalence of delayed eruption of permanent upper central incisors at a tertiary hospital in Riyadh, Saudi Arabia. Children. 2022; 9: 1781.
46. Mohammed S, Saloom J, Obaid D, Alhuwaizi A. Malocclusion traits and speech disorders. Med J Babylon. 2024; 20: 661-4.
47. Weinberg B. A cephalometric study of normal and defective –s– articulation and variations in incisor dentition. J Speech Hear Res. 1968; 11: 288-300.