Hematomukometra kot netipična predstavitev raka endometrija pri ženski po menopavzi

Hematomucometra as an Atypical Presentation of Endometrial Carcinoma in a Postmenopausal Woman

Avtor / Author

Ustanova / Institute

Alen Lipčić[1], Nermin Karahasan[1], Barjes El Aklouk[1], Dubravko Habek[2]

[1]Klinika za ženske bolesti i porode, Klinička bolnica Merkur, Zagreb, Hrvatska;

[2]Klinika za ženske bolesti i porode, Klinička bolnica Merkur, Zagreb, Hrvatska, Medicinski fakultet Hrvatskog katoličkog sveučilišta, Akademija medicinskih znanosti Hrvatske, Zagreb, Hrvatska

[1]University Department of Gynecology and Obstetrics Clinical Hospital Merkur Zagreb;

[2]University Department of Gynecology and Obstetrics Clinical Hospital Merkur Zagreb, School of Medicine Catholic University of Croatia, Croatian Academy of Medical Sciences, Zagreb, Croatia

Ključne besede:
hematomukometra, pomenopavza, rak endometrija, bolečina v trebuhu

Key words:
hematomucometra, postmenopause, endometrial carcinoma, abdominal pain

Članek prispel / Received
25. 11. 2025
Članek sprejet / Accepted
22. 6. 2026

Naslov za dopisovanje / Correspondence
Alen Lipčić, MD, University Department of Gynecology and Obstetrics Clinical Hospital Merkur Zagreb, +385 99 548 9646, alenlipcic@gmail.com

Izvleček

Namen: *Predstaviti redko in netipično klinično manifestacijo hematomukometre, povezane z rakom endometrija pri ženski po menopavzi.*

Predstavitev primera: *72-letna bolnica po menopavzi je več mesecev navajala bolečine v spodnjem delu trebuha, brez vaginalne krvavitve ali izcedka. Klinični pregled in slikovne preiskave so pokazali 15 cm veliko medenično maso, ki je ustrezala razširjeni maternici z gosto intrauterino vsebino in intraluminalnim izrastkom velikosti do 3 cm. Tumorski označevalci so bili blago povišani, vnetni markerji pa so ostali v mejah referenčnih vrednosti. Eksplorativna laparotomija je razkrila povečano, makroskopsko spremenjeno maternico z videzom »peščene ure«.*

Abstract

Purpose: *To present a rare and atypical clinical manifestation of hematomucometra associated with endometrial carcinoma in a postmenopausal woman.*

Case presentation: *A 72-year-old postmenopausal patient presented with several months of lower abdominal pain without vaginal bleeding or discharge. Clinical examination and imaging revealed a 15 cm pelvic mass corresponding to a distended uterus with dense intrauterine contents and an intraluminal excrescence as large as 3 cm. Tumor markers were mildly elevated, while inflammatory markers remained within reference values. Exploratory laparotomy revealed an enlarged, macroscopically altered*

https://doi.org/10.18690/actabiomed.311, CC BY 4.0
© 2026 Avtor(ji) / The Author(s)

Evakuiranih je bilo približno 500 mL čokoladno obarvane, viskozne in ne smrdeče vsebine, mikrobiološka analiza pa je pokazala sterilen vzorec. Opravljena je bila totalna abdominalna histerektomija z obojestransko adneksektomijo. Histopatološka preiskava je potrdila endometrioidni adenokarcinom endometrija, slabo diferenciran (stopnje 3), FIGO IC.

Zaključek: *Hematomukometra je lahko netipična predstavitev raka endometrija pri ženskah po menopavzi, tudi ob odsotnosti vaginalne krvavitve ali izcedka. Vztrajajoča bolečina v trebuhu in razširjena maternica zato zahtevata temeljito ginekološko obravnavo.*

uterus with an "hourglass" appearance. Approximately 500 ml of chocolate-colored, viscous, non-fetid content was evacuated and microbiological analysis was sterile. Total abdominal hysterectomy with bilateral adnexectomy was performed. Histopathology confirmed grade 3 endometrioid adenocarcinoma of the endometrium, FIGO Ic.

Conclusion: *Hematomucometra may represent an atypical presentation of endometrial carcinoma in postmenopausal women, even in the absence of vaginal bleeding or discharge. Persistent abdominal pain and uterine distension should therefore prompt thorough gynecological evaluation.*

INTRODUCTION

Hematometra and pyometra are gynecological entities characterized by the accumulation of blood or pus within the uterine cavity, because of impaired or obstructed cervical canal drainage. These conditions are most frequently observed in postmenopausal women, in whom the incidence is approximately 0.2%, whereas in patients with endometrial carcinoma (EC), the incidence ranges between 1.5% and 4%. The clinical presentation is often nonspecific and may include symptoms such as vaginal discharge, bleeding, fever, uterine enlargement, and lower abdominal pain. The frequency of pyometra significantly increases with advanced age, reduced physical activity, urinary incontinence, diabetes mellitus, and poor hygiene[1,2]. Hematomucometra (HMM) is an extremely rare entity involving retention of blood and mucus within the uterine cavity. We report this case because of its atypical clinical presentation in the setting of EC,after having obtained the patient's consent and approval from our hospital's ethics committee.

CASE REPORT

A 72-year-oldpostmenopausal patient (P1), who had been postmenopausal since 50 years of age, was admitted to the emergency department of our gynecology clinic because of several months of severe lower abdominal pain. She had been repeatedly evaluated in emergency settings, but because of her dementia and poor socioeconomic circumstances, which contributed to delayed gynecological and radiological evaluation, no comprehensive workup had been performed. She denied vaginal bleeding or discharge.Significant findings in her medical history included poorly controlled arterial hypertension and type II diabetes mellitus. A physical examination revealed a painful palpable pelvic mass measuring approximately 15 cm in the hypogastrium. A speculum examination showed atrophic upper vaginal walls without secretion, and the external cervical os could not be visualized. A digital rectal examination indicated an enlarged cervix occupying the entire pelvis and a relatively small uterine corpus. Her pap smear was normal, without atypical cells. Because of vaginal semi-occlusion, hysteroscopy or curettage could not be performed. Cervical dilatation under anesthesia was not considered feasible, because of the inability to identify the external cervical os and marked anatomical distortion.

Transvaginal ultrasound demonstrated a cystic mass filled with opalescent material, measuring 11 × 8 cm. No ovaries or free abdominal fluid were visualized. On

admission, uncontrolled type II diabetes mellitus was noted (blood glucose 25.8 mmol/L); consultation with a diabetologist led to administration of rapid-acting insulin, which achieved satisfactory glycemic control. Preoperative laboratory and imaging evaluation were performed. Tumor markers were mildly elevated: CEA, 5.2 µg/L (reference value <3.8); CA-125, 62.7 kIU/L (reference value <35.0). Inflammatory markers (CRP and leukocyte count) remained within reference values. Because the patient was afebrile,preoperative antibiotic therapy was not administered. Multislice computed tomography (MSCT) of the chest, abdomen, and pelvis revealed a relatively well-defined bilobular pelvic mass involving the uterine cavity and cervix; filled with dense, possibly mucinous material; and measuring 15.1 × 8.5 × 19.5 cm. A centrally hypodense intramural lesion (0.8 cm) was noted in the uterine fundus, along with an endoluminal proliferative lesion as large as 3 cm, which was inseparable from the uterine wall. No pelvic or abdominal lymphadenopathy or pathological adnexal findings were observed. The bladder was compressed but intact, with no intraluminal abnormalities. Minimal pelvic free fluid was present (Figure 1). Given the patient's postmenopausal status, tumor markers, MSCT findings, and ASA III classification, an exploratory Joel-Cohen laparotomy was performed. Intraoperatively, an enlarged "hourglass-shaped" uterus was identified, with a softened corpus and a lower uterine segment approximately twice the size of the corpus, with intact perimetrium and normal adnexa. During uterine manipulation, viscous, chocolate-colored, non-fetid contents leaked from the thinned uterine wall; approximately 500 ml was aspirated and sent for microbiological analysis, and was found to be sterile. A total abdominal hysterectomy with bilateral adnexectomy was performed (Figure 2). Postoperative antibiotic therapy with 1 g cefazolin was administered three times daily.

Histopathology confirmed endometrioid adenocarcinoma of the endometrium, G3. The postoperative course was uneventful. The patient was discharged in good general condition with controlled diabetes and referred for further oncological treatment according to histopathological findings.

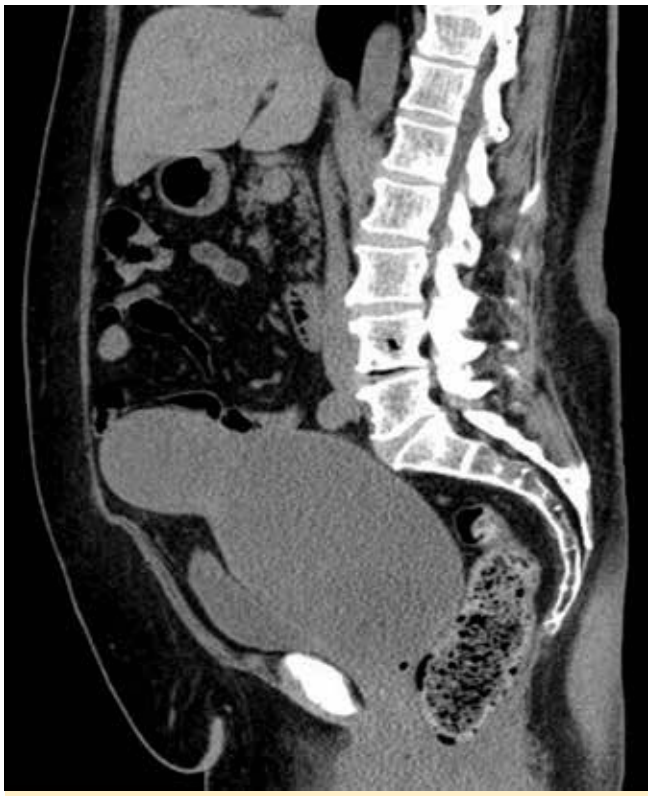

Figure 1. *MSCT scan showing a distended uterus filled with dense content and showinga markedly thinned myometrium.*

DISCUSSION

Prolonged blood retention within the uterine cavity leads to breakdown of hemoglobin into hematin, thus conferring a chocolate-brown appearance. When this blood combines with mucus degeneration, a thick adhesive material, characteristic of HMM, is formed. Although pyometra has been most frequently described in postmenopausal women as pus retention due to necrotic debris, most often secondary to endometrial malignancy, and mucometra is occasionally reported because of mucous secretion of the endometrial glands, HMM represents an unusual combination of hematinized hematometra and mucometra.

These entities all cause uterine distension and intermittent cramping pain, historically described as Simpson's cramps [3,4]. Our patient presented exclusively with prolonged abdominal pain and

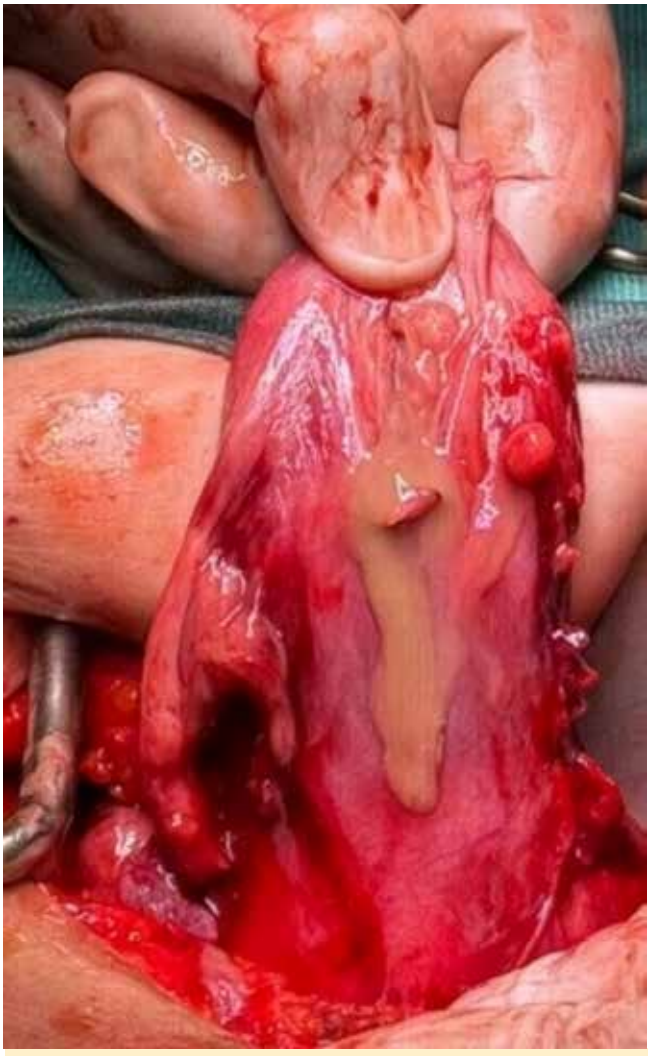

Figure 2. *Intraoperative finding of hematomucometra with chocolate-like content.*

a large palpable pelvic mass, without the typical symptoms of pyometra such as bleeding or purulent discharge. In one retrospective study spanning 8 years, the most common symptoms in women with confirmed pyometra were postmenopausal bleeding (59.2%), vaginal discharge (40.8%), fever (6.6%), and abdominal pain (5.3%) [5]. Another retrospective cohort study in 192 patients found abdominal pain in 49.0% and vaginal discharge in 47.9% of patients [6]. Therefore, our case highlights that HMM can present solely with abdominal pain, thus potentially complicating timely diagnosis. The absence of vaginal bleeding or discharge was probably associated with severe cervical ostium stenosis and the highly viscous nature of the retained intrauterine content.Our patient's laboratory results were within reference limits, except for elevated CA-125 (62.7 kIU/L), a finding also described in the literature. Unlike the case reported by Febriany etal. [2], our patient had inflammatory markers within reference values, thus excluding infection and supporting the diagnosis of non-infectious HMM. Mendoza et al. have described a case of massive pyometra with elevated CA-125 (214 U/ml), in which the rise was attributed to inflammation rather than malignancy[7]. This finding highlights the nonspecific nature of CA-125, particularly in postmenopausal women with pyometra, and the need for histopathological confirmation to establish malignancy. Microbiological analysisof the aspirated uterine content showed no bacterial growth, thereby suggesting a sterile exudate. In a study by Ikeda et al., *Escherichia coli*, *Bacteroides*, and *Peptococcus species* were most common in isolates, whereas no pathogens were identified in 8% of cases, in agreement with our findings [8].

Atypical benign presentations of pyometra and pyosalpinx in postmenopausal women have previously been reported [9]. Histopathology in our patient revealed endometrioid adenocarcinoma of the endometrium, G3, representing an aggressive high-grade form that atypically manifested as prolonged HMM. The dense, viscous nature of the retained content prevented spontaneous evacuation through the vagina. Among malignant tumors associated with intrauterine content retention, EC is most common, and is followed by cervical carcinoma [10].

This case demonstrates an atypical clinical manifestation of HMM, more precisely hematomuco-trachelometra, with a cervix distended to twice the volume of the uterine corpus. The viscous adhesive content produced no discharge but instead caused severe abdominal pain in a postmenopausal patient with EC as the underlying disease.

AUTHOR CONTRIBUTION

All authors read and approved the final version of the manuscript.

DECLARATIONS

The authors declare that they have no competing interests.

ETHICAL STANDARDS

For images or other information within the manuscript which identify patients, consent was obtained from them.

REFERENCES

1. Kerimoglu OS, Pekin A, Yilmaz SAet al. Pyometra in elderly post-menopausal women: a sign of malignity. Eur J Gynaecol Oncol. 2015;36:59zczc-61.
2. Febriany DC, Hameed Sultan MA, Ahmad Sharifuddin Z, Thangavelu AR, Chin C. The dual danger of pyometra and endometrial carcinoma: a case report. Ital J GynaecolObstet. 2024;36:168.
3. Walthall L, Heincelman M. Pyometra: An Atypical Cause of Abdominal Pain. J Investig Med High Impact Case Rep. 2021;9:23247096211022481.
4. Habek D. et al. Textbook of Obstetrics and Gynecology. Medicinska naklada Publisher Zagreb, 2025.
5. Lui MW, Cheung VY, Pun TC. Clinical Significance of Pyometra. J Reprod Med. 2015;60:329zczc-32.
6. Jang S, Jeon M, Mun SJ et al. Clinical characteristics and risk factors for septic shock in patients with pyometra: A retrospective multicentercohort study. J Infect Public Health. 2024;17:862zczc-67.
7. Ortiz Mendoza CM. Giant piometra originating high serum levels of CA-125. Ginecol Obstet Mex. 2009 ;77:445zczc-48.
8. Ikeda M, Takahashi T, Kurachi H. Spontaneous perforation of pyometra: a reportof seven cases and review of the literature. Gynecol Obstet Invest. 2013;75:243zczc-49.
9. Habek D. Pyometra and bilateral pyotuboovarium in an 84-year-old woman. Eur J Obstet Gynecol Reprod Biol. 2005;123:258zczc-60.
10. Tal Bliman Y, Rafaeli Yehudai T, Shiber Y et al. Spontaneous pyometra in postmenopausal women and gynecologic cancer-a preliminary study based on experience of a tertiary medical center. Menopause. 2025;https://doi.org/10.1097/GME.0000000000002600.