

# Raba PRECLUDE® perikardialne e-PTFE membrane v oftalmologiji

## Use of the PRECLUDE® pericardial e-PTFE membrane in ophthalmology

Avtor / Author

Ustanova / Institute

Aneja Gorišek<sup>1</sup>, Dušica Pahor<sup>1,2</sup>

<sup>1</sup>Univerzitetni klinični center Maribor, Oddelek za očne bolezni, Maribor, Slovenija;

<sup>2</sup>Univerza v Mariboru, Medicinska fakulteta, Maribor, Slovenija;

<sup>1</sup>University Medical Centre Maribor, Department of Ophthalmology, Maribor, Slovenia;

<sup>2</sup>University of Maribor, Faculty of Medicine, Maribor, Slovenia;

### Ključne besede:

PRECLUDE® perikardialna membrana, ekspaniran politetrafluoroetilen (e-PTFE), Gore-Tex membrana, perforiran roženčni ulkus, refraktorni glavkom

### Key words:

PRECLUDE® pericardial membrane, expanded polytetrafluoroethylene (e-PTFE), Gore-Tex Patch, perforated corneal ulcer, refractory glaucoma

### Članek prispel / Received

10. 4. 2024

### Članek sprejet / Accepted

11. 4. 2024

### Naslov za dopisovanje / Correspondence

Prof. dr. Dušica Pahor, dr. med.

d.pahor@ukc-mb.si

Tel: 00386 2 321 1630

### Izvleček

*Namen prispevka je obravnavati vsestransko rabo PRECLUDE® perikardialne e-PTFE membrane na področju oftalmologije.*

*E-PTFE membrana je varna in učinkovita pri pokrivanju globokega ali perforiranega roženičnega ulkusa kot alternativna kirurška metoda. Predstavlja dodatno metodo izbora pokrivanja roženičnega defekta za ohranitev zrkla ali odložitev transplantacije roženice, kar je pomembno še posebej pri imunsko prizadetih bolnikih. Po odstranitvi membrane se lahko izvede za nekaj mesecev odložena penetrantna keratoplastika kot dokončna oblika zdravljenja, ki ima boljšo prognozo, kot je "à-chaud" keratoplastika.*

*E-PTFE membrana se lahko uporablja po trabekulektomiji pri sekund-*

### Abstract

*This article provides an overview of the diverse applications of the PRECLUDE® pericardial e-PTFE membrane in ophthalmology.*

*The e-PTFE membrane was found to be safe and effective as an alternative surgical procedure for perforating corneal ulcer closures. It could be a method of choice for eye preservation or during delayed corneal transplantation, especially in immunocompromised patients. After membrane removal, penetrating keratoplasty can be performed as a definitive treatment with better prognosis as "à-chaud" keratoplasty in all eyes, as a prognosis of visual acuity improvement is expected.*

*E-PTFE membrane implantation for use after uneventfully performed trabeculectomy with*

*arnih refraktornih glavkomih, še posebej po poškodbi, kjer je kljub operaciji intraokularni pritisk neurejen. Gre za novo dodatno obliko zdravljenja sekundarnih glavkomov. E-PTFE membrano lahko uporabimo v tistih primerih, kjer je tveganje uporabe antimetabolitov visoko. Naš nov kirurški pristop po trabekulektomiji je preprost in varen ter se lahko uporablja za izboljšanje filtracije pri vseh oblikah refraktornih glavkomov.*

*still-uncontrolled postoperative intraocular pressure (IOP) in severe refractory glaucoma represents an additional approach for treating uncontrolled secondary glaucoma. This modified trabeculectomy can be used as surgical treatment and for refractory traumatic glaucoma cases. The e-PTFE membrane can be used in cases where antimetabolite-related risk must be avoided. Our new surgical treatment after trabeculectomy is a simple and safe procedure and can be used as a filtration-modulating device in all refractory glaucomas.*

## INTRODUCTION

The PRECLUDE® pericardial membrane, also known as a Gore-Tex Patch, is made of expanded polytetrafluoroethylene (e-PTFE) and is considered one of the most inert and biocompatible materials. This non-absorbable material has unique features, including microporosity, tightness at low pressure, gas and water vapour permeabilities, and minimal tissue adhesion during reconstructive procedures (1).

The PRECLUDE® pericardial membrane enables control over the ingrowth of tissue and artificial surfaces by adjusting the size of the interstitial space. The membrane thickness is 0.1 mm with a pore size of less than 1 µm. This small pore size prevents tissue ingrowth and limits adhesion between the membrane and surrounding structures. Histological examination of explanted e-PTFE membranes reveals loosely adherent cells at the tissue-membrane interface with no evidence of collagen or cell infiltration. The PRECLUDE® pericardial membrane is a white, opaque material that becomes wet and is transparent after implantation due to proteinaceous and aqueous fluid. This occurs in 2–6 weeks and is facilitated by the material's thin and microporous qualities (2-8).

The e-PTFE membrane is one of the most chemically inert and biocompatible materials known. It is a fluoropolymer comprised of several solid nodes interconnected by a matrix of thin fibrils. E-PTFE's hydrophobicity can prevent the wound area from postoperatively adhering to adjacent tissue, and can

promote epithelisation with minimal inflammatory responses. The peculiarity of this non-absorbable material is microporosity, water tightness at low pressure, gas and water vapour permeabilities, and the ability to minimise tissue attachment to the material in reconstructive procedures. R. Gore patented expanded polytetrafluoroethylene (e-PTFE) as a highly stable polymer of tetrafluoroethylene in 1976 (1). The main feature of e-PTFE is its ability to be incorporated into a wide range of tissues, and its approval for use in a wide range of biomedical implantation procedures (9-12). The PRECLUDE® pericardial membrane is used in various fields of medicine. The material is used in vascular surgery as vascular grafts, bypass grafts, hernia membranes, plastic surgery, reconstructive cardiac surgeries, gynaecological surgery, and sutures (13-19). In this review article, we discuss the versatile use of the PRECLUDE® pericardial membrane in ophthalmology.

## USE OF THE PRECLUDE® PERICARDIAL MEMBRANE FOR PERFORATED CORNEAL ULCER CLOSURE

Perforated corneal ulcers must be treated surgically. For smaller corneal perforations, a therapeutic contact lens or tissue glue can be used (20,21). For larger corneal defects, keratoplasty "à-chaud" is indicated. These procedures are usually associated with poor functional results (9,15).

The treatment of perforated corneal ulcers with “à-chaud” keratoplasty in patients with systemic autoimmune inflammatory diseases often leads to postoperative complications, such as poor epithelial formation and wound healing, repeated corneal melting processes, and a higher risk of graft rejection (15-18). The e-PTFE membrane (W. L. Gore & Associates, Flagstaff, AZ, USA) is made of expanded polytetrafluoroethylene, otherwise known as Gore-Tex, which is considered a chemically inert fabric and a biocompatible material.

In immunological ulcers, it is recommended to delay keratoplasty for 6–12 weeks to achieve a better postoperative outcome. During this time, systemic immunosuppression can be initiated to gain better control of the local inflammatory response. Systemic immunologically mediated inflammation suppression requires adequate immunomodulatory treatment and close coordination with an experienced rheumatologist (15,18).

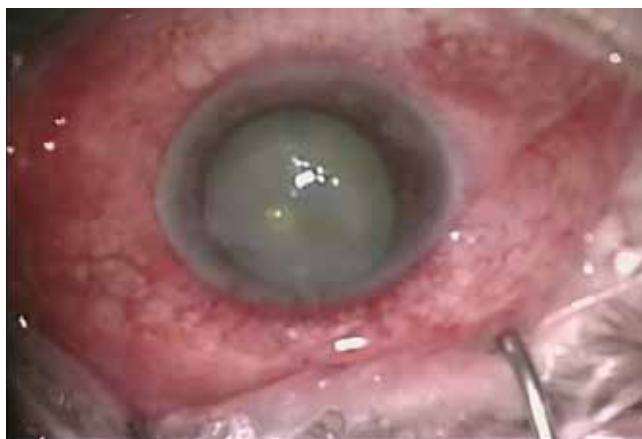The e-PTFE membrane was first used in corneal perforation by Legeais et al. in 1991 (20). Ophthalmic surgeons previously did not widely use the PRECLUDE® pericardial membrane. There are only a few reports on the use of e-PTFE for provisional corneal coverage in corneal perforation (21,22). In a study by Amm and Nolle, the e-PTFE membrane was used to cover an immunological non-perforated corneal ulcer with descemetocoele in six patients. This prevented corneal perforation, and the plastic implant sealed the anterior chamber (15). Rüfer et al. successfully treated 39 eyes, including 13 with ulcer perforation, with the e-PTFE membrane (23).

E-PTFE consists of numerous solid knots interwoven with thin fibres throughout a matrix. This non-absorbable material's unique features are its microporosity, watertightness at low pressure, gas and water vapour permeabilities, and minimal tissue adhesion in reconstructive procedures. The usefulness of e-PTFE membranes has been demonstrated in experimental and clinical studies (15,16,21-24).

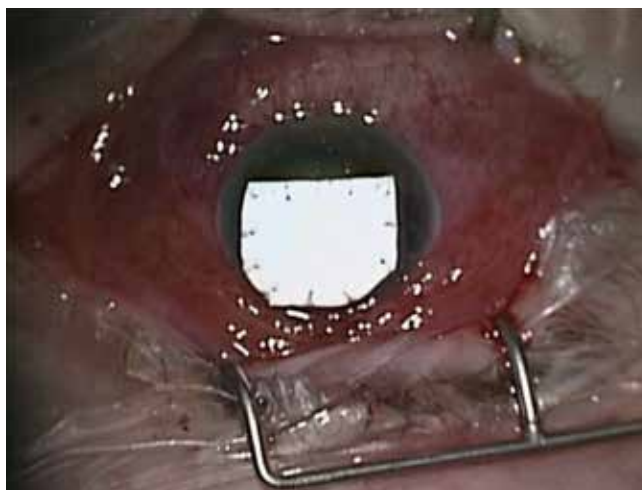
Pahor et al. treated three patients with perforated corneal ulcers suffering from systemic autoimmune inflammatory diseases: a 53-year-old male patient with granulomatosis with polyangiitis, a 66-year-old female

patient with systemic vasculitis with sclerokeratitis, and a 56-year-old male patient with Sjögren's syndrome. Systemic immunosuppression was initiated by a rheumatologist (18).

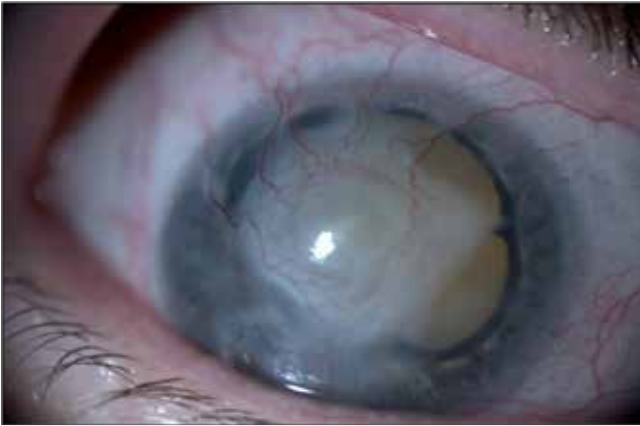Corneal perforation was successfully covered with an e-PTFE membrane, and the anterior chamber was reconstructed (Figs. 1 and 2). None of the patients had any pain or other complaints. No sign of infection or inflammation was observed during the follow-up.



**Figure 1.** Large, deep corneal ulcer with a small perforation (by permission of Full Prof. Dušica Pahor).



**Figure 2.** The membrane was fixated to the healthy cornea with several non-absorbable sutures (Prolen 10.0), and the anterior chamber was reconstructed (by permission of Full Prof. Dušica Pahor).



**Figure 3.** *Three months after surgical treatment, the e-PTFE membrane was removed. The underlying cornea was thin, firm, stable, and completely vascularised, and the deep anterior chamber was normal. Intraocular pressure was normal after treatment with local anti-glaucoma medication (by permission of Full Prof. Dušica Pahor).*

The follow-up period was free of complications. The e-PTFE membrane was removed 3 months after the surgical procedure in the patient with granulomatosis with polyangiitis and in the patient with vasculitis, and 8 months after the surgical procedure in the patient with Sjögren's syndrome. The underlying cornea was thin, firm, stable, and completely vascularised (Fig. 3). Intraocular pressure was normal in all cases; in case 1, local pressure-reducing treatment was required. In all patients, intraocular pressure was measured using digital tonometry.

The e-PTFE membrane enables control over the adhesion of tissue and artificial surfaces. The membrane thickness is 0.1 mm with a pore size of less than 1  $\mu\text{m}$ . This small pore size prevents tissue ingrowth and limits adhesion between the membrane and surrounding structures. Histologically examined e-PTFE membranes that were explanted showed loosely adherent cells at the tissue-membrane interface, with no evidence of collagen or cell infiltration. The PRECLUDE<sup>®</sup> pericardial membrane is a white, opaque material that becomes wet and is transparent after

implantation due to proteinaceous and aqueous fluid. This is due to the microporous and thin properties of the material; the process occurs within 2–6 weeks (15,18).

E-PTFE shows common biocompatibility and biostability. Its hydrophobic properties prevent the wound area from adhering to the surrounding tissue postoperatively. Previous studies have shown that e-PTFE promoted epithelialisation, caused a minimal inflammatory response, and prevented conjunctival re-adhesion (13,14,25-27).

In our patients, non-absorbable sutures (polypropylene monofilament 10.0) were used. In all cases, we used patches with a larger surface area than the melting perforated ulcers. Special attention was directed to the design of the appropriate membrane size. If the membrane was too small, the tissue and material were strained, which led to suture tears. If the membrane was too large, this led to wrinkling and incorrect positioning. A sufficiently large section of membrane was cut to cover the melting cornea and anchor the sutures to the firm healthy cornea, thus avoiding suture complications. Resuturing was not necessary in our cases. In all cases, only a 0.1 mm thick membrane layer was used. No recipient trephination or corneal preparation for the patch was performed.

In our patients, the perforated ulcers were almost centrally localised. Although the e-PTFE membrane was opaque, the anterior chamber could be examined and analysed through the peripheral cornea. This is an advantage compared to amniotic membrane transplants. In two patients, visual acuity before perforation was limited to light perception and hand movement. Our first patient was already blind.

Another advantage of this treatment is that it can be carried out under local anaesthetic, which is especially important for patients with systemic autoimmune inflammatory diseases.

E-PTFE is commercially available. There is no need for a corneal bank, as is the case with preparing the amniotic membrane. Numerous studies have shown that the amniotic membrane usually reepithelialises. It is more suitable for covering minor non-perforating ulcers for better wound healing. The amniotic membrane is not sufficiently stable in perforated corneal ulcers



larger than 2 mm. In ulcers larger than 3 mm, fibrin glue was used to stabilise the multilayered amniotic membrane. The insertion of the e-EPTF membrane is therefore an alternative for the treatment of larger ulcer perforations.

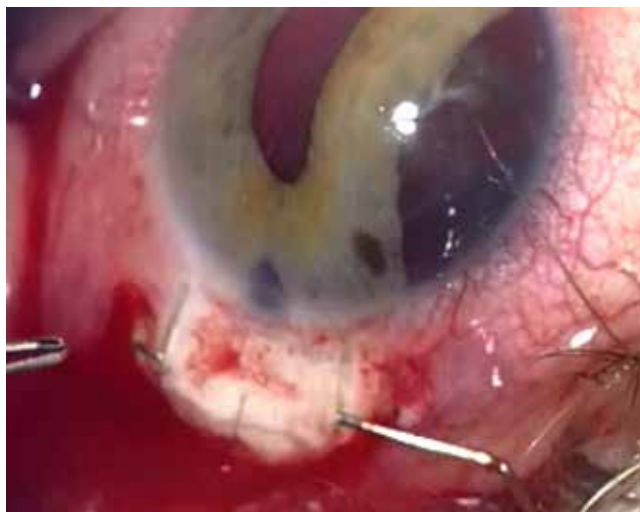Patients with immune-mediated corneal ulcers usually require 2–3 months to benefit from intensive local and systemic immunosuppressive therapies (15-16,23). A temporary e-PTFE membrane can reduce the high risk of graft rejection. In the study of Rufer et al., three-quarters of patients could be treated with elective keratoplasty after the initial Gore-Tex patch insertion (23). It is of great importance that no epithelialisation or progressive vascularisation is observed at the membrane. The membrane does not stimulate immune responses, which could increase the risk of graft rejection during a subsequent corneal transplant.

With regard to the systemic disease, our patients' eyes were significantly affected. In the first and second cases, we aimed to preserve the eye, and in the third, to prepare it for further surgery.

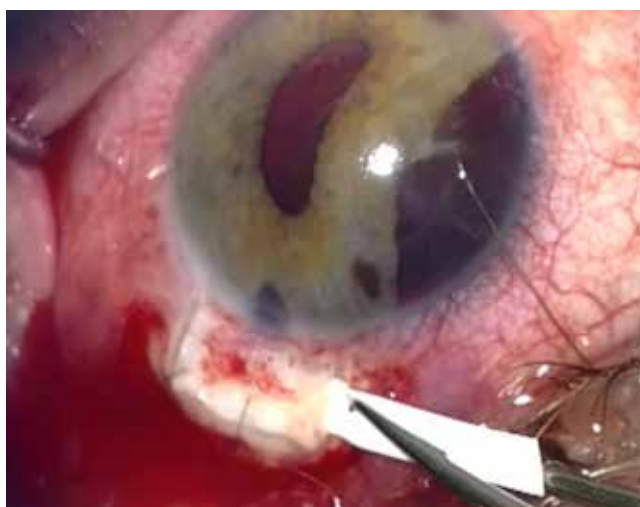Our study confirmed the results of previous studies that the PRECLUDE® pericardial membrane provides an alternative to surgical treatment of corneal ulcer perforations in patients with systemic autoimmune inflammatory diseases. In high-risk patients at risk of graft rejection, this procedure could be the method of choice for eye preservation and deferred corneal transplantation.

## **A NEW SURGICAL TECHNIQUE FOR THE TREATMENT OF SECONDARY REFRACTORY POST-TRAUMATIC GLAUCOMA AFTER TRABECULECTOMY WITH THE PRECLUDE® PERICARDIAL MEMBRANE**

Since the first description of trabeculotomy in 1968, it has become a standard in the surgical treatment of glaucoma. With this fistulising treatment, a drainage system is created through which the aqueous humour is drained from the anterior chamber of the eye into the subconjunctival space to reduce intraocular pressure.



*Figure 4. A very thin spatula was used for complete dissection of the flap from the underlying sclera (by permission of Full Prof. Dušica Pahor).*



*Figure 5. The proper size of the PRECLUDE® pericardial membrane band was obtained by cutting with a scissors approximately 7 mm long and 2 mm bright. The membrane was grasped with fine forceps, as gently as possible, and pushed under the scleral flap (by permission of Full Prof. Dušica Pahor).*

Trabeculotomy is still the most effective treatment for patients with progressive glaucoma (28,29). The most common cause for failure of trabeculotomy for glaucoma surgery is fistula blockage caused by

ingrowth of fibrous tissue or adhesion of the scleral flap to the scleral bed (29).

In contrast to many other procedures that aim for complete healing, trabeculotomy aims for an incomplete wound healing response to allow permanent drainage of the aqueous humour from the anterior chamber through the fistula (28). The healing process in glaucoma surgery must be adjusted frequently to achieve the appropriate pressure (30). Despite significant advances in surgical techniques and postoperative care, excessive scarring and fibrosis due to increased human conjunctival fibroblast proliferation and the accumulation of extracellular matrix of the subconjunctival tissue, as well as scleral buckling, remain the leading causes of filtering bleb failure (31,32).

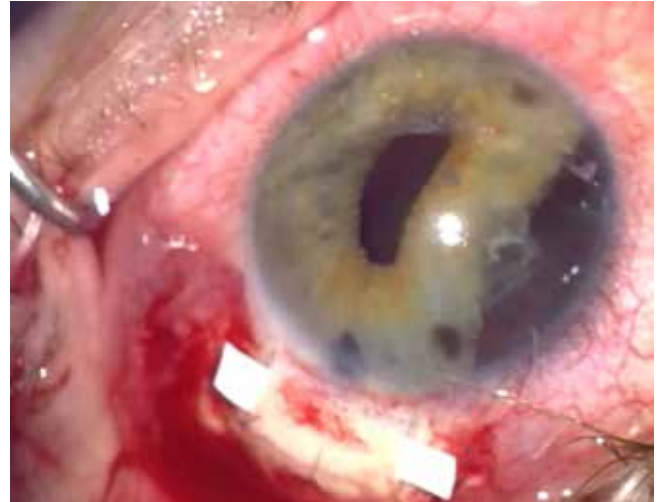Numerous attempts have been made to halt this process, including the use of mechanical barriers or antiproliferative agents. However, alternative strategies are still needed to prevent failures of surgical interventions that follow excessive wound healing.

Refractory glaucoma is a severe disease that is very difficult to treat. It is usually associated with severe ocular pathologies, such as secondary neovascular glaucoma and severe ocular injury, especially as a result of blunt trauma to the eye that does not respond to medical treatment, laser therapy, or surgical interventions to reduce intraocular pressure. Filtering glaucoma surgery, as well as trabeculotomy with or without antimetabolites, Nd-YAG laser use, diode laser cyclophotocoagulation, and endoscopic cyclophotocoagulation are methods that successfully reduce intraocular pressure in refractory glaucoma in the short and medium term (33).

The success percentage of filtering surgery in regular glaucoma patients is 70%–90%, whereas in refractory glaucoma, it is only 11%–52% (28,34,35).

The upper scleral flap is removed from the lower scleral bed with a very thin spatula and cauterised (Fig. 4).

A Gore® PRECLUDE® pericardial membrane measuring 8.0 × 16.0 cm and a thickness of 0.1 mm was used. A small section was cut from the membrane,



**Figure 6.** *The membrane was grasped with fine forceps, as gently as possible, and pushed under the scleral flap (by permission of Full Prof. Dušica Pahor).*

from which a 7 mm long and 2 mm wide band was then produced as an implant for covering (Fig. 5).

The e-PTFE implant was placed under the scleral flap with a spatula and not sutured in place. The membrane was then pulled over the underlying scleral bed with fine forceps, leaving a membrane margin of 1–2 mm on both sides of the lid (Fig. 6). The membrane under the lid was stable. The lid and the underlying membrane were covered with conjunctiva, and both membrane edges could be seen under the lid.

Our results suggest that the implantation of an e-PTFE membrane under the scleral flap after a trabeculotomy is a new surgical technique for treating secondary refractory post-traumatic glaucoma.

This new method is a simple and safe procedure that can also be used as filtration in all post-traumatic refractory glaucoma, especially in patients where anti-metabolite-related risk must be avoided. However, further studies are needed to confirm this surgical method as simple and safe for all types of refractory glaucoma, particularly when anti-metabolite-related risk must be avoided.

## FURTHER INDICATIONS FOR THE USE OF E-PTFE IN OPHTHALMOLOGY

Because e-PTFE is a chemically inert, non-antigenic tissue well tolerated in situ, it is widely used in ophthalmology. E-PTFE has been used as a substitute for silicone seals in scleral buckle surgery and strabismus surgery for muscle stretching (36). E-PTFE has also been used as a scleral graft fibre in coralline hydroxyapatite porous orbital implantation after enucleation, and as a mucosal substitute in patients with anophthalmic cavities to keep adjacent bulbar and palpebral wounds separate and prevent rescarrying (37). E-PTFE also works well as a substitute material for spacers in treating lower eyelid retraction (38). It has also been used as a reinforcement material in glaucoma drainage systems (39-42). In scarring conditions, such as severe alkaline chemical injury or ocular pemphigoid, e-PTFE has been used as a spacer to prevent eyelid melting and to remodel the upper eyelid or conjunctival fold (43-45). Multi-microporous insertion of the e-PTFE membrane can provide starting points for new therapies for treating complicated multiple recurrent pterygia (46). It is increasingly used as Gore-Tex sutures for sclera fixated intraocular lenses and frontalis suspension for congenital ptosis (47-50).

## CONCLUSION

The e-PTFE membrane is a safe and effective alternative surgical procedure for perforating corneal ulcer closure. It could be the method of choice for eye preservation or delayed corneal transplantation, especially in immunocompromised patients. After membrane removal, penetrating keratoplasty can be performed as a definitive treatment in all eyes where a prognosis of visual acuity improvement is expected. E-PTFE membrane implantation following uneventfully performed trabeculectomy with still-uncontrolled postoperative IOP in severe refractory glaucoma represents an additional approach for treating uncontrolled secondary glaucoma. This modified trabeculectomy can be used for surgical treatment and for refractory traumatic glaucoma cases. The e-PTFE membrane can also be used in cases where antimetabolite-related risk must be avoided. Our new surgical treatment after trabeculectomy is a simple and safe procedure and can be used as a filtration-modulating device in all refractory glaucoma. Overall, e-PTFE is a chemically inert, non-antigenic tissue well tolerated in situ, with many applications in ophthalmology.

## REFERENCES

1. Gore R. Process for producing porous products. US 3953566. 1976.
2. Venugopal A, Ravindran MGore-tex a magic sheet for symblepharon prevention! Indian J Ophthalmol. 2022 Oct;70(10):3745. doi: 10.4103/ijo.IJO\_515\_22. PMID: 36190104
3. Hanel KC, McCabe C Abbott WM, et al. Current PTFE grafts, a biomechanical scanning electron, and light microscopic evaluation. Am Sur 1982; 195: 456-63.
4. Sojer T, Lempinen M, Cooper P. A new venpus prosthesis. Surgery 1972; 72: 864-72.
5. Sakamoto T, Imai Y, Koyanagi H, et al. Clinical use of expanded polytetrafluoroethylene in cardiac surgery. Kyobu Geka 1978; 31: 23-9.
6. Meus PJ, Wernly JA, Campbell CD, et al. Long-term evaluation of pericardial substitutes. J Thorac Cardiovasc Surg 1983; 85: 54-8.
7. Monk BJ, Fowler JM, Burger RA, et al. Expanded polytetrafluoroethylene is an effective barrier in preventing pelvic adhesions after radical surgery for ovarian cancer. Int J Gynecol 1998; 8: 403-8.
8. Giovanni A, Vallicioni J, Gras R, et al. Clinical experience wirth Gore-Tex for vocal fold medialization. Laryngoscope 1999; 198: 284-8.
9. Batniji RK, Hutchinson JL, Dahiya R, et al. Tissue response to expanded polytetrafluoroethylene and silicone implants in a rabbit model. Arch Facial Plast Surg 2002; 4: 111-3.
10. Sterling GM,. Animal toxicities study of a promising new contraceptive device. Gynaecol Endosc 2002; 11: 137-40.
11. Kawaguchi T, Hosoda K, Shibata Y, et al. Expanded polytetrafluoroethylene membrane for prevention of adhesions in patients undergoing external decompression and subsequent cranioplasty. Neurol Med Chir 2003; 43: 320-3.
12. Karesh JW, Fabrega MA, Rodrigues MM. Interpositional polytetrafluoroethylene grafts. Conjunctival biocompatibility. Ophthal Plast Reconstr Surg 1991; 7:278-83.
13. Minale C, Nikol S, Hollweg G, et al. Clinical experience with expanded polytetrafluoroethylene Gore-Tex surgical membrane for pericardial closure: a study of 110 cases. J Card Surg 1988; 3: 193-201.
14. Leprince P, Rahmati M, Bonnet N, et al. Expanded polytetrafluoroethylene membranes to wrap surfaces of circulatory support devices in patients undergoing bridge to heart transplantation. Eur J Cardiothorac Surg 2001; 19: 302-6.
15. Amm M, Nölle B. Gore-tex(r) patch in immunologically conditioned corneal ulcer. Klin Monbl Augenheilkd. 2002 Oct;219(10):735-9. doi: 10.1055/s-2002-35689. PMID: 12447718
16. Pahor D, Pahor A. E-PTFE Membrane for the Management of Perforated Corneal Ulcer, Klin Monbl Augenheilkd. 2016 Oct;233(10):1156-1162. doi: 10.1055/s-0042-102963. Epub 2016 Jul 6. PMID: 27385258
17. Pleyer U, Bertelmann E, Rieck P, et al. Outcome of penetrating keratoplasty in rheumatoid arthritis. Ophthalmologica 2002; 216(4): 249-55.
18. PAHOR, Artur, PAHOR, Dušica. PRECLUDE Pericardial Membrane für die Behandlung von perforiertem Hornhautulkus bei Patienten mit systemischen autoimmunentzündlichen Erkrankungen. Spektrum der Augenheilkunde. 2014, bd. 28, hft. 4, str. 160-166, ilustr. ISSN 0930-4282. <http://link.springer.com/article/10.1007/s00717-014-0227-4>, DOI: 10.1007/s00717-014-0227-4
19. PAHOR, Dušica, GRAČNER, Tomaž. Eine neue Operationstechnik für die Behandlung von sekundären refraktären posttraumatischen Glaucomen nach Trabekulektomie mit PRECLUDE pericardial membrane : eine Fallbeschreibung. Spektrum der Augenheilkunde. [Online ed.]. 2019, vol. 33, iss. 4, str. 74-80, ilustr. ISSN 1613-7523. <https://link.springer.com/article/10.1007/s00717-019-0428-y>, <https://doi.org/10.1007/s00717-019-0428-y>,



- DOI: 10.1007/s00717-019-0428-y. [COB
20. Legeais JM, Renard G, D'Hermies F, et al. Surgical management of corneal perforation with expanded polytetrafluoroethylene (Gore-Tex). *Ophthalmic Surg* 1991; 22(4): 213-217.
  21. Anitha V, Ravindran M, Ghorpade A. Gore-Tex- as an adjuvant to Tenon's patch graft for large perforated corneal ulcers during Covid times. *Am J Ophthalmol Case Rep.* 2022 Mar; 25:101322. doi: 10.1016/j.ajoc.2022.101322. Epub 2022 Jan 24. PMID: 35097239
  22. Akpek EK, Aldave AJ, Amescua G, Colby KA, Cortina MS, de la Cruz J, Parel JA, Li G. Twelve-Month Clinical and Histopathological Performance of a Novel Synthetic Cornea Device in Rabbit Model. *Transl Vis Sci Technol.* 2023 Aug 1; 12(8):9. doi: 10.1167/tvst.12.8.9. PMID: 37561510
  23. Ruffer F, Eisenack J, Klettner A, et al. Multilayered Gore-Tex Patch for temporary coverage of deep noninfectious corneal defects: surgical procedure and clinical experience. *Am J Ophthalmol* 2011; 151: 703-13.
  24. Nobe JR, Moura BT, Robin JB, et al. Results of penetrating keratoplasty for the treatment of corneal perforations. *Arch Ophthalmol* 1990; 108: (7): 939-941.
  25. Schmidt T, Kohler W. Fornix reconstruction in ocular pemphigoid with Goretext surgical membrane. *Ophthalmology* 1997; 94:321-3.
  26. Ling Yuh K. Polytetrafluoroethylene as a wrapping material for a hydroxyapatite orbital implant. *Ophthalmic Plastic Reconstructive Surgery* 2000; 16 (4): 286-8.
  27. Tawakol ME, Peyman GA, Liu KR, et al. Gore tex soft tissue bands as scleral explants in rabbits: a preliminary histologic study. *Ophthalmic Surg* 1989; 20: 199-201.
  28. Lama PJ, Fechtner RD. Antifibrotic and wound healing in glaucoma surgery. *Surv Ophthalmol.* 2003; 48(3): 314-46.
  29. Caprioli J, de Leon JM, Azarbod P, et al. Trabeculectomy can improve long-term visual function in glaucoma. *Ophthalmology* 2016; 123: 117-28. Doi.10.1016/j.optha.2015.09.027.
  30. Addicks EM, Quigley HA, Green WR, et al. Histologic characteristics of filtering blebs in glaucomatous eyes. *Arch Ophthalmol* 1983; 101:795-8. Doi:10.1001/archophth.1983.01040010795021.
  31. Cordeiro MF, Chang L, Lim ks, et al. Modulating conjunctival wound healing- *Eye* 2000; 14: 536-47.
  32. Broadway DC, Chang IP. Trabeculectomy, risk factors for failure and the preoperative state of the conjunctiva. *J Glaucoma* 2001; 10: 237-49.
  33. Gedde SJ, Schiffman JC, Feuer WJ, et al. Tube versus Trabeculectomy Study Group. Treatment outcomes in the Tube Versus Trabeculectomy (TVT) study after five years of follow-up. *Am J Ophthalmol* 2012; 153(5): 789. e2-803.e2.
  34. Harasymowycz P, Birt C, Gooi P, et al. Medical management of glaucoma in the 21 st century from a Canadian perspectives. *J Ophthalmol* 2016; 2016: 6509809.
  35. Razeghinejad MR, Fundemberg SJ, Spaeth GL, et al. The changing conceptual basis of trabeculectomy: a review of past and current surgical techniques. *Surv Ophthalmol* 2012; 57(1): 1-25.
  36. Wu PC, Sheu JJ, Chen YH, Chen YJ, Chen CH, Lee JJ, et.al Gore-Tex vascular graft for macular buckling in high myopia eyes. *Retina.* 2017 Jul; 37(7):1263-1269. doi: 10.1097/IAE.0000000000001376. PMID: 27984549
  37. Kao LY. Polytetrafluoroethylene as a wrapping material for a hydroxyapatite orbital implant. *Ophthalmic Plast Reconstr Surg.* 2000 Jul; 16(4):286-8. doi: 10.1097/00002341-200007000-00006. PMID: 10923976
  38. Steinsapir KD, Steinsapir S. The Treatment of Post-blepharoplasty Lower Eyelid Retraction. *Facial Plast Surg Clin North Am.* 2021 May; 29(2):291-300. doi: 10.1016/j.fsc.2021.01.006. Epub 2021 Apr 24. PMID: 33906761 Review.

39. Bicket AK, Szeto J, Roeber P, Towler J, Troutman M, Craven ER, et al. A novel bilayered expanded polytetrafluoroethylene glaucoma implant creates a permeable thin capsule independent of aqueous humor exposure. *Bioeng Transl Med*. 2020 Aug 22;6(1):e10179. doi: 10.1002/btm2.10179. eCollection 2021 Jan. PMID: 33532583 Free PMC article.
40. Park J, Rittiphairoj T, Wang X, E JY, Bicket AK. Device-modified trabeculectomy for glaucoma. *Cochrane Database Syst Rev*. 2023 Mar 13;3(3):CD010472. doi: 10.1002/14651858.CD010472.pub3. PMID: 36912740 Free PMC article.
41. Samaeili A, Rahmani S, Hassanpour K, Meshksar A, Ansari I, Afsar-Aski S, et al. Rom J Ophthalmol. 2021 Apr-Jun;65(2):150-156. doi: 10.22336/rjo.2021.30. PMID: 34179580
42. Niegowski LJ, Bravetti GE, Gillmann K, Mansouri K, Mermoud A. Pericardium Patch Graft (Tutoplast) for Bleb Repair and Bleb Remodelling After Nonpenetrating Filtering Surgery: 6-Month Outcomes. *J Glaucoma*. 2020 May;29(5):347-350. doi: 10.1097/IJG.0000000000001474. PMID: 32097253
43. Venugopal A, Ravindran M. Gore-tex a magic sheet for symblepharon prevention! *Indian J Ophthalmol*. 2022 Oct;70(10):3745. doi: 10.4103/ijo.IJO\_515\_22. PMID: 36190104 Free PMC article.
44. Venugopal A, Gurnani B, Ravindran M, Uduman MS. Management of symblepharon with Gore-tex as a novel treatment option for ocular chemical burns. *Eur J Ophthalmol*. 2024 Mar 5;11206721241238302. doi: 10.1177/11206721241238302. Online ahead of print. PMID: 38444229
45. Demirci H, Elnor SG, Elnor VM. Rigid nylon foil-anchored polytetrafluoroethylene (Gore-Tex) sheet stenting for conjunctival fornix reconstruction. *Ophthalmology*. 2010 Sep;117(9):1736-42. doi: 10.1016/j.ophtha.2010.01.061. Epub 2010 Aug 5. PMID: 20691479.
46. Kim KW, Kim JC, Moon JH, Koo H, Kim TH, Moon NJ. Br Management of complicated multirecurrent pterygia using multimicroporous expanded polytetrafluoroethylene. *J Ophthalmol*. 2013 Jun;97(6):694-700. doi: 10.1136/bjophthalmol-2012-302784. Epub 2013 Mar 15. PMID: 23505304
47. Leuzinger-Dias M, Lima-Fontes M, Rodrigues R, Oliveira-Ferreira C, Madeira C, Falcão-Reis F, et al. Scleral Fixation of Akreos AO60 Intraocular Lens Using Gore-Tex Suture: An Eye on Visual Outcomes and Postoperative Complications. *J Ophthalmol*. 2021 Dec 20;2021:9349323. doi: 10.1155/2021/9349323. eCollection 2021. PMID: 34966559
48. Patel NA, Fan KC, Yannuzzi NA, Fortun JA, Haddock LJ, Yoo SH, et al. Refractive Outcomes of Four-Point Scleral Fixation of Akreos AO60 Intraocular Lens Using Gore-Tex Suture. *Clin Ophthalmol*. 2020 Dec 21;14:4431-4437. doi: 10.2147/OPHTH.S282094. eCollection 2020. PMID: 33376297
49. Pardini D, Lucatto LF, Junior OM, Maia A, Hammamji K, Dirani A, et al. Outcomes of Pars Plana Vitrectomy and 4-Point Sutured Scleral Fixation of Akreos AO60 Intraocular Lens in Clinical Settings: A Case Series. *Ophthalmol Retina*. 2023 Jan;7(1):59-66. doi: 10.1016/j.oret.2022.07.006. Epub 2022 Jul 16. PMID: 35850442
50. Ma L, Zhang L, Liu Z, Wang D, Li Y, Zhang C. Application of e-PTFE Frontalis Suspension in the Treatment of Congenital Ptosis in Children. *Front Surg*. 2022 May 16;9:904307. doi: 10.3389/fsurg.2022.904307. eCollection 2022. PMID: 35651689