

Prikaz primera hudega poteka pljučnice povzročene z virusom Varicella-Zoster, zdravljene z aciklovirjem in zunajtelesno membransko oksigenacijo

Severe Varicella-Zoster virus pneumonia in a healthy young adult treated with acyclovir and extracorporeal membrane oxygenation: a case report

Avtor / Author

Luka Varda¹, Metin Omerović², Barbara Kit³, Franc Svenšek^{3,4}, Jure Fluher^{3,4}, Iva Cestar³, Martin Marinšek^{3,4}, Andrej Markota^{3,4}

Ustanova / Institute

¹Univerzitetni klinični center Maribor, Klinika za interno medicine, Oddelek za dializo, Maribor, Slovenija; ²Univerzitetni klinični center Maribor, Urgentni center, Maribor, Slovenija; ³Univerzitetni klinični center Maribor, Klinika za interno medicine, Oddelek za intenzivno interno medicine, Maribor, Slovenija; ⁴Univerza v Mariboru, Medicinska fakulteta, Maribor, Slovenija;

¹University Medical Centre Maribor, University Division of Internal Medicine, Department of Dialysis, Maribor, Slovenia; ²University Medical Centre Maribor, Emergency Center, Maribor, Slovenia; ³University Medical Centre Maribor, University Division of Internal Medicine, Department of Intensive Internal Medicine, Maribor, Slovenia; ⁴University of Maribor, Faculty of Medicine, Maribor, Slovenia;

Ključne besede:

Varicella-Zoster virus, pljučnica, zunajtelesna membranska oksigenacija, cor pulmonale, prikaz primera

Key words:

Varicella-zoster virus, pneumonia, extracorporeal membrane oxygenation, cor pulmonale, case report

Članek prispel / Received

24. 3. 2024

Članek sprejet / Accepted

4. 6. 2024

Naslov za dopisovanje / Correspondence

Luka Varda, University Medical Centre Maribor, University Division of Internal Medicine, Department of Dialysis, Maribor, Ljubljanska ulica 5, 2000 Maribor, Slovenia
E-mail: luka.varda@ukc-mb.si

Izvleček

Namen: Okužba z virusom Varicella-zoster (VZV) je pogosta pri otrocih in običajno poteka benigno. Pri odraslih se lahko kaže kot huda primarna virusna pljučnica z akutno odpovedjo dihanja in ima veliko stopnjo smrtnosti.

Prikaz primera: 32-letni, predhodno zdrav moški je obiskal Urgentni center z gripi podobnimi simptomi, brez kakršnegakoli izpuščaja. Tri dni kasneje se je vrnil z razširjenim kožnim izpuščajem in hudim sindromom akutne dihalne stiske, ki je zahteval intubacijo in mehansko ventilacijo. Potrdili smo primarno okužbo z VZV. Mehanska ventilacija ni bila zadostna, zato je bila uvedena venovenska zunajtelesna membranska oksigenacija. Poleg podpornih ukrepov je bil pacient zdravljen z intravenskim acik-

Abstract

Purpose: Varicella-zoster virus (VZV) infection is common in children and is usually benign. In adults VZV infection can present as a severe primary viral pneumonia with acute respiratory failure. VZV infections in adult have a high mortality rate.

Case report: A 32-year-old previously healthy male first presented to the emergency department with flu-like symptoms and no rash. Three days later he returned to the emergency department with a disseminated skin rash and severe acute respiratory distress syndrome that required intubation and mechanical ventilation. A VZV infection was confirmed. Mechanical ventilation was insufficient and venovenous extracorporeal membrane oxygenation was introduced. In addition

lovirjem. Med hospitalizacijo se je pojavilo več zapletov, in sicer hud cor pulmonale, kar je zahtevalo zdravljenje z dušikovim oksidom in milrinonom, diseminirana intravaskularna koagulacija, kar je zahtevalo menjavo zunajtelesne membrane, in ventilatorska pljučnica. Po 27 dneh je bil odpuščen domov.

Zaključek: Klinični potek primarne okužbe z VZV je v odrasli dobi povezan s številnimi zapleti. Zgodnje prepoznavanje akutne odpovedi dihanja, ventilacijska podpora in zgodnja raba aciklovirja so ključni elementi zdravljenja pljučnice VZV.

to supportive measures, he was treated with intravenous acyclovir. During hospitalisation he developed several complications, including severe cor pulmonale necessitating treatment with nitrous oxide and milrinone, disseminated intravascular coagulation necessitating an extracorporeal membrane change, and ventilator-associated pneumonia. He was discharged home in stable condition on hospital day 27.

Conclusion: Primary VZV infection in adulthood is associated with several complications. Early recognition of acute respiratory failure, ventilatory support, and early administration of acyclovir are crucial elements of VZV pneumonia treatment.

INTRODUCTION

Varicella-zoster virus (VZV) is a pathogenic human virus in the *Herpesviridae* family. As a primary infection, VZV causes chickenpox (varicella). Varicella usually occurs during childhood in geographic regions where the varicella vaccine is not included in the national vaccination programme. Following the primary infection, the virus becomes latent in peripheral ganglionic neurons and can reactivate in later years or decades as herpes zoster (shingles) (1).

Acute varicella is typically a self-limiting and benign infection in immunocompetent children. Adults, immunocompromised patients, pregnant women, and neonates, however, are at higher risk for more severe infections (2). Herein we present a case involving a previously healthy 32-year-old male who developed severe VZV pneumonia with complications and required venovenous extracorporeal membrane oxygenation (VV-ECMO) treatment.

CASE PRESENTATION

A previously healthy 32-year-old male presented to the emergency department (ED) with a 2-day history of malaise, dry cough, and fever to 39°C. The

clinical examination revealed inspiratory crackles in the lower right lung field. The laboratory test results were within normal ranges except for an elevated C-reactive protein [CRP] 100 mg/L. A chest radiograph was normal (Figure 1). Due to the respiratory tract infection without identification of the pathogen, he was discharged home with empiric antibiotic therapy (azithromycin).

Three days later he returned to the ED with signs of severe respiratory failure (peripheral oxygen saturation = 55% on a non-rebreather face mask) and a disseminated vesicular rash that was most prominent on the face and anterior thorax. He was intubated in the ED after pre-oxygenation with non-invasive ventilation. Severe combined hypoxemic and hypercapnic respiratory failure persisted despite neuromuscular paralysis and mechanical ventilation with high positive end-expiratory pressure [PEEP] (12 cmH₂O) and fraction of inspired oxygen [FiO₂] (100%). After admission to the intensive care unit (ICU), PEEP was titrated to 18 cmH₂O according to transpulmonary pressure measurement with an oesophageal catheter. However, he deteriorated further with decreasing lung compliance and worsening respiratory failure. Within 12 h after presenting to the ED, VV-ECMO support was initiated; the PaO₂/FiO₂ before VV-ECMO support was 89.2 mmHg, indicating severe acute respiratory

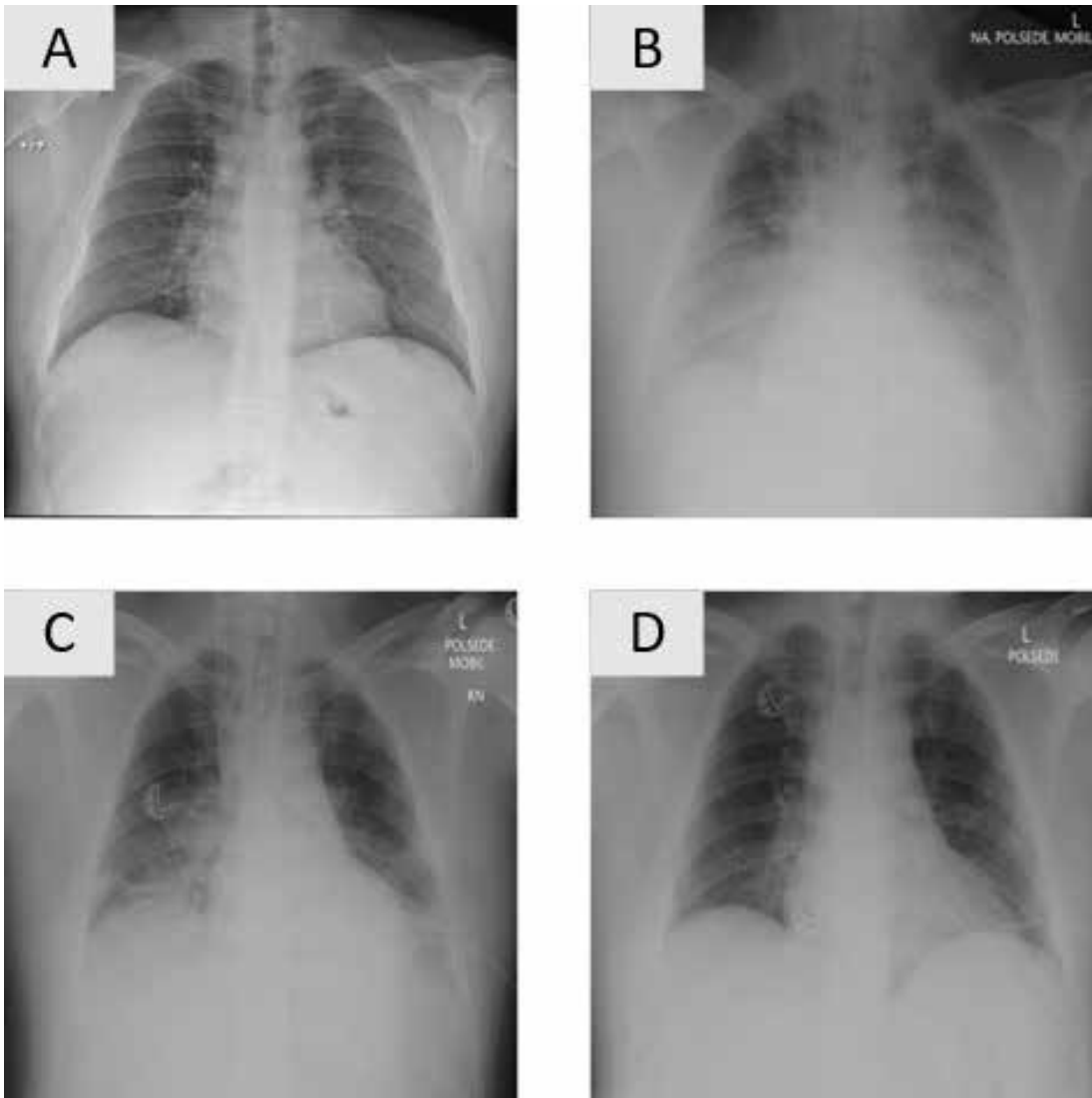


Figure 1. Chest X-ray at various times during treatment.

A – Normal chest X-ray at first admission to the emergency department.

B – Chest X-ray showing severe bilateral consolidations after V-V ECMO initiation.

C – Chest X-ray showing regression of consolidations during hospitalisation.

D – Chest X-ray before hospital discharge.

distress syndrome. He required noradrenaline (approximately 0.2 mcg/kg/min) to maintain his blood pressure. The maximum lactate in the first 12 h was 3.2 mmol/l.

A chest radiograph immediately after insertion of the ECMO cannulae revealed extensive bilateral infiltrates (Figure 1). At the time of hospital admission, the laboratory results were remarkable for elevated inflammatory markers (CRP, 252 mg/L;

leukocyte count, $25 \times 10^9/L$; and procalcitonin, 0.61 ng/mL), mild hyponatremia (132 mmol/L), and acute kidney injury (creatinine, 132 $\mu\text{mol/L}$). Extensive microbiological samples (Table 1) were obtained and empiric antiviral therapy with acyclovir was initiated 3 h after his arrival to the ED and 6 h before initiating VV-ECMO. Ceftriaxone and azithromycin were initiated in the ED within the 1st h after the admission. On day 2, positive PCR

Table 1. Microbiological testing and results during hospitalisation

TYPE OF MICROBIOLOGICAL TEST	DAY OF HOSPITALIZATION	RESULT
Haemocultures	1	Negative
A swab of the skin vesicle for the DNA sequence of the monkeypox virus (PCR)	1	Negative
Swab of the skin vesicle for DNA sequence of HSV1, HSV2, VZV, and human enteroviruses (PCR)	1	POSITIVE FOR VZV
Urine sample – antigen for <i>Legionella pneumophila</i> and <i>Streptococcus pneumoniae</i>	1	Negative
Tracheal aspirate for bacterial cultures	1	Negative
Specific blood antibodies for VZV (ELISA) - IgG	1	Borderline
Specific blood antibodies for SARS-CoV-2 (CLIA) – IgM and IgG	1	Negative
Specific blood antibodies for <i>Treponema pallidum</i>	1	Non-reactive
Viral hepatitis and HIV antibodies (HBsAg, anti-HCV, anti-HIV-1/HIV-2, and HIV p24Ag)	1	Non-reactive
Tracheal aspirate for the DNA sequence of VZV (PCR)	2	POSITIVE FOR VZV
Supervisory microbiological cultures for resistant bacteria (a swab of the nose, pharynx and skin for MRSA; a swab of the rectum for ESBL, CRPs, CRAb, CRE, and VRE; urine sample from the urinary catheter for ESBL, CRPs, CRAb, and CRE; and tracheal aspirate for ESBL, CRPs, CRAb, and CRE)	2	Negative
Specific blood antibodies for VZV (ELISA) – IgM and IgG	4	POSITIVE for IgM (4188; positive if >1.1) and IgG (3080 IU/L; positive if >110 IU/L)
Tracheal aspirate for bacterial cultures	5	Negative
Supervisory microbiological cultures for resistant bacteria (a swab of the nose, pharynx and skin for MRSA; a swab of the rectum for ESBL, CRPs, CRAb, CRE, and VRE; urine sample from the urinary catheter for ESBL, CRPs, CRAb, and CRE; and tracheal aspirate for ESBL, CRPs, CRAb, and CRE)	8	Negative
Left bronchial aspirate for bacterial cultures	9	Negative
Control haemocultures	9	Negative
Control haemocultures	13	Negative
Tracheal aspirate for bacterial cultures	13	<i>Achromobacter</i> spp.
Semi-quantitative urine culture	13	Negative
Tracheal aspirate for bacterial cultures	15	Negative
Tracheal aspirate for bacterial cultures	16	<i>Kluyveromyces lactis</i>
Supervisory microbiological cultures for resistant bacteria (a swab of the nose, pharynx and skin for MRSA; a swab of the rectum for ESBL, CRPs, CRAb, CRE, and VRE; urine sample from the urinary catheter for ESBL, CRPs, CRAb, and CRE; and tracheal aspirate for ESBL, CRPs, CRAb, and CRE)	16	NEGATIVE

DNA – deoxyribonucleic acid; PCR – polymerase chain reaction; HSV1 – herpes simplex virus 1; HSV2 – herpes simplex virus 2; ELISA – enzyme-linked immunosorbent assay; CLIA - chemiluminescent immunoassay; HCV – hepatitis C virus; HIV – human immunodeficiency virus; MRSA – methicillin-resistant *Staphylococcus aureus*; ESBL – extended spectrum beta-lactamases; CRPs – carbapenem-resistant *Pseudomonas* species; CRAb – carbapenem-resistant *Acinetobacter baumannii*; CRE – carbapenem-resistant Enterobacteriaceae; VRE – vancomycin-resistant *Enterococcus*

tests for VZV were obtained from tracheal aspirates and skin vesicle swabs.

On hospital day 5, the noradrenaline requirement increased to approximately 0.6 mcg/kg/min. A bedside cardiac ultrasound revealed that the right ventricle was approximately the same size as the left ventricle and the estimated left ventricular ejection fraction was 50%. There were no signs of pericardial effusion and the inferior vena cava diameter was 1.9 cm. A pulmonary embolism was ruled out with computed tomography angiography of the pulmonary arteries. Acute cor pulmonale was attributed to hypoxic vasoconstriction because of extensive lung infiltrates. The $\text{PaO}_2/\text{FiO}_2$ was 93.8 mmHg. Therefore, a continuous infusion of milrinone and nitric oxide inhalation were added. Over the next 2 days, the noradrenaline infusion rate was decreased. Bedside echocardiography revealed normalisation of right ventricular function, therefore milrinone and nitric oxide were gradually discontinued. Daily bronchoscopic lavages were performed due to copious tracheal aspirates but only superficial mucosal erosions were observed. Subsequent chest radiographs revealed some improvement. On hospital day 9, the inflammatory marker levels increased again and additional purulent aspirates were present. Due to suspected ventilator-associated pneumonia, meropenem was initiated empirically. However, the tracheal aspirates remained sterile. On the same day, the VV-ECMO run was complicated by thrombosis of the ECMO membrane despite anticoagulation with an infusion of standard heparin and disseminated intravascular coagulation developed. The ECMO membrane was replaced and further ECMO treatment was unremarkable. The patient was successfully decannulated on hospital day 12. With improvement in the chest radiography findings (Figure 1), he was weaned from mechanical ventilation. He was extubated on hospital day 15, discharged from the ICU on hospital day 18, and discharged to home in stable condition on hospital day 27.

DISCUSSION

A case of severe VZV pneumonia in a young, previously healthy adult was presented. In children, VZV usually begins simultaneously with a generalised, pruritic, vesicular rash, and fever. In adults a prodrome of headache, malaise, and fever can precede the development of the rash. Adults, immunocompromised patients, pregnant women, and neonates are at higher risk for more severe VZV infections with systemic complications. Diagnosis of a VZV infection is usually based on clinical signs and symptoms (1, 2). The current patient first presented with a fever and mild cough; and clinical and laboratory signs consistent with a lower respiratory tract infection. During the next 3 days he developed signs of severe respiratory failure, which suggested the possibility of a severe course of a generally very common disease.

It is likely that the current patient did not have a previous VZV infection. His mother confirmed that he had an infection with a rash as a child that was thought to be varicella. However, IgG antibodies were borderline-positive 5 days after the onset of symptoms, and IgG and IgM antibodies were clearly positive 3 days later. Therefore, the current infection was most likely the primary infection with VZV, whereas the childhood rash was likely caused by another childhood viral disease that with a characteristic rash (3).

In addition to empiric antibiotic therapy, the patient was treated with intravenous acyclovir. A clear benefit has been shown when the latter is administered < 24 h after the onset of the rash (4). In previous case reports, ECMO was mostly used in patients with VZV pneumonia who were at high risk for severe respiratory failure, including a pregnant woman (5), child with acute lymphoblastic leukaemia (6), patient who subsequently developed a lymphoma, and another with immunoglobulin deficiency (7). Lee et al. (8) and White et al. (9) described 7 and

14 patients who were treated with ECMO in the 1980s and 1990s with survival rates 57% and 71%, respectively. Reports of VZV patients who required ECMO in the last 10 years are limited (10, 11). The current patient developed acute cor pulmonale during ECMO, which we attributed to severe hypoxic vasoconstriction, and which was treated with nitrous oxide and milrinone. In fact, there are no descriptions of nitrous oxide or milrinone use in this setting (12).

The use of corticosteroids in the treatment of VZV pneumonia is controversial. There have been cases in which corticosteroids, in addition to standard therapy, have successfully treated primary VZV pneumonia (13, 14). However, clinical trials have yet to be conducted on this topic. We decided against the use of corticosteroids based on the assumption that the patient had an active viral infection rather than an excessive inflammatory response.

Determining the prognosis of VZV pneumonia is difficult. Our patient was young and immunocompetent with no chronic diseases or ongoing therapy. According to Inokuchi et al. (15), bronchoscopy findings can be useful in predicting VZV pneumonia outcomes. Extensive and deep mucosal ulcerations of the airways have more fatal outcomes than shallow, limited, or no ulcerations (15). The bronchoscopy findings in the current case revealed superficial mucosal erosions only and were therefore in agreement with the Inokuchi et al. (15) findings.

CONCLUSION

VZV infection can cause severe primary pneumonia in some healthy young adults. Early administration

of acyclovir should be considered when antiviral treatment is indicated. When mechanical ventilation is insufficient, VV-ECMO remains an option. To avoid initiation of veno-arterial ECMO, nitric oxide and milrinone can be used for the treatment of severe cor pulmonale. Administration of corticosteroids is controversial in primary VZV pneumonia and should be considered on an individual basis. Bronchoscopy findings can be helpful in determining the outcome of VZV pneumonia.

CONFLICT OF INTEREST

No conflicts of interest to declare.

FORMATTING OF FUNDING SOURCES

This research did not receive any specific grant from funding agencies in the public, commercial, or not-for-profit sectors.

DECLARATION OF INTERESTS

The authors declare that they have no known competing financial interests or personal relationships that could have appeared to influence the work reported in this paper.

ETHICAL APPROVAL SENTENCE

A written consent was obtained from the patient to present anonymised medical data.

REFERENCES

1. Gershon AA, Breuer J, Cohen JI, Cohrs RJ, Gershon MD, Gilden D, et al. Varicella zoster virus infection. *Nat Rev Dis Primers*. 2015;1:15016.
2. Gershon AA, Gershon MD. Pathogenesis and current approaches to control of varicella-zoster virus infections. *Clin Microbiol Rev*. 2013;26(4):728-43.
3. Min SW, Kim YS, Nahm FS, Yoo DH, Choi E, Lee PB, et al. The positive duration of varicella zoster immunoglobulin M antibody test in herpes zoster. *Medicine (Baltimore)*. 2016;95(33):e4616.
4. Mohsen A, McKendrick M. Varicella pneumonia in adults. *European Respiratory Journal*. 2003;21(5):886-91.
5. Clark G, Dobson P, Thickett A, Turner N. Chickenpox pneumonia, its complications and management: a report of three cases, including the use of extracorporeal membrane oxygenation. *Anaesthesia*. 1991;46(5):376-80.
6. Hicks RE, Kinney TR, Raphaely RC, Donaldson MH, Edmunds Jr LH, Naiman JL. Successful treatment of varicella pneumonia with prolonged extracorporeal membrane oxygenation in a child with leukemia. *The Journal of Thoracic and Cardiovascular Surgery*. 1977;73(2):297-302.
7. Claydon AH, Nicholson KG, Wiselka MJ, Firmin RK. Varicella pneumonitis: a role for extra-corporeal membrane oxygenation? *J Infect*. 1994;28(1):65-7.
8. Lee WA, Kolla S, Schreiner RJ, Jr., Hirschl RB, Bartlett RH. Prolonged extracorporeal life support (ECLS) for varicella pneumonia. *Crit Care Med*. 1997;25(6):977-82.
9. White RW, Peek GJ, Jenkins DR, Killer HM, Firmin RK. Extracorporeal membrane oxygenation for chickenpox pneumonia: a single institution's experience. *ASAIO journal*. 2003;49:378-82.
10. Tong T, Wong O, Kwan G, Chan K. A case of severe varicella pneumonia requiring extracorporeal membrane oxygenation. *Hong Kong Journal of Emergency Medicine*. 2016;23(1):51-4.
11. Nauka P, Hasan Z, Hilewitz A, Koenig S, Chen L, Gong J. Varicella pneumonia in an immunocompetent adult with interstitial lung disease (ILD) requiring veno-venous extracorporeal membrane oxygenation (VV-ECMO). *Chest*. 2019;156(4):A2053-A4.
12. Bugge J, Tanbo T. Nitric oxide in the treatment of fulminant pulmonary failure in a young pregnant woman with varicella pneumonia. *European journal of anaesthesiology*. 2000;17(4):269-72.
13. Corrigan R, Carter R, Raza M. Use of steroids for management of varicella pneumonia. *Case Reports*. 2015;2015:bcr2015210866.
14. Ahmed R, Ahmed Q, Adhami N, Memish Z. Varicella pneumonia: another 'steroid responsive' pneumonia? *Journal of chemotherapy*. 2002;14(2):220-2.
15. Inokuchi R, Nakamura K, Sato H, Shinohara K, Aoki Y, Doi K, et al. Bronchial ulceration as a prognostic indicator for varicella pneumonia: Case report and systematic literature review. *Journal of Clinical Virology*. 2013;56(4):360-4.