

# Ventrikularne aritmije in srčni zastoj pri zastrupitvi z akonitinom: prikaz primera

## Ventricular arrhythmias and cardiac arrest in aconitine poisoning: a case report

**Avtor / Author**

**Ustanova / Institute**

Nino Cmor<sup>1</sup>, Gašper Razinger<sup>2</sup>, Jure Fluher<sup>3,4</sup>, Andrej Markota<sup>3,4</sup>

<sup>1</sup>Splošna bolnišnica Murska Sobota, Interni oddelek, Kardiološki odsek, Murska Sobota, Slovenija; <sup>2</sup>Univerzitetni klinični center Ljubljana, Center za klinično toksikologijo in farmakologijo, Ljubljana, Slovenija; <sup>3</sup>Univerzitetni klinični center Maribor, Klinika za interno medicino, Oddelek za intenzivno interno medicino, Maribor, Slovenija; <sup>4</sup>Univerza v Mariboru, Medicinska fakulteta;

<sup>1</sup>General Hospital Murska Sobota, Division of Cardiology, Murska Sobota, Slovenia;

<sup>2</sup>University Medical Centre Ljubljana, Center for Clinical Toxicology, Ljubljana, Slovenia;

<sup>3</sup>University Medical Centre Maribor, University Division of Internal Medicine, Department of Intensive Internal Medicine, Maribor, Slovenia; <sup>4</sup>University of Maribor, Faculty of Medicine

### Ključne besede:

prekatne aritmije, srčni zastoj, zastrupitev z akonitinom, oživiljanje, amiodaron

### Key words:

ventricular arrhythmias, cardiac arrest, aconitine poisoning, cardiopulmonary resuscitation, amiodarone

### Članek prispel / Received

3. 3. 2024

### Članek sprejet / Accepted

21. 5. 2024

### Naslov za dopisovanje / Correspondence

Nino Cmor MD, General Hospital Murska Sobota, Division of Cardiology, Ulica dr. Vrbnjaka 6, 9000 Murska Sobota, Slovenia; [nino.cmor@gmail.com](mailto:nino.cmor@gmail.com)

### Izvleček

Akonitin je strupen alkaloid iz gomoljev preobjede *Aconitum napellus*, ki se po temeljitem procesiranju v tradicionalni kitajski medicini uporablja predvsem za lajšanje mišično-kostnih bolečin. V primeru neustrezne predelave ali zaužitja večje količine akonitinskega preparata se lahko pojavi zastrupitev. Zaradi specifične toksikodinamike akonitina se ob njegovi zastrupitvi pogosto pojavljajo ventrikularne motnje ritma, kot so ventrikularne ekstrasistole, ventrikularna tahikardija, ventrikularna fibrilacija in torsades de pointes. Ob zastrupitvi z akonitinom je potrebno zelo skrbno zdravljenje le-teh. V tem članku predstavljamo klinični primer ventrikularnih motenj ritma ob

### Abstract

In traditional Chinese medicine, aconitum plants and roots are frequently used after extensive processing to treat various ailments in humans. However, use of a larger than recommended dose and inadequate processing increase the risk of aconitine poisoning. As a result of its particular mechanism of toxicity, aconitine poisoning can present with a variety of arrhythmias, including ventricular ectopy, ventricular tachycardia, ventricular fibrillation, and torsades de pointes. Meticulous arrhythmia treatment is needed to restore sinus rhythm. We report a case of ventricular arrhythmias (VAs) induced by accidental aconitine poisoning. Our case highlights the efficacy of amiodarone

nenamerni zastrupitvi z akonitinom. Prikazan primer poudarja antiaritmično učinkovitost amiodarona pri zdravljenju z akonitinom sproženih ventrikularnih aritmij in je ob tem med prvimi v Evropi, ki opisuje ventrikularne aritmije ob zastrupitvi z akonitinom. Z opisanim primerom želimo zdravnike opozoriti na redke toksikološke vzroke malignih aritmij in jih v primeru etiološko nepojasnjene nenadne srčne smrti usmeriti k toksikološkemu testiranju.

in treating aconitine-induced VAs. To the best of our knowledge, this is one of the first described cases of aconitine-induced VAs in Europe. Clinicians should be aware of potential rare toxicological causes of malignant arrhythmias and consider toxicological screening in otherwise etiologically unexplained sudden cardiac arrest.

## INTRODUCTION

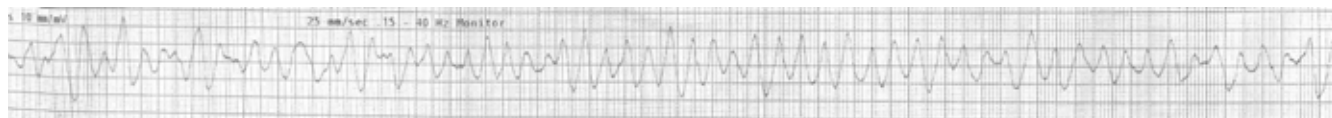Aconitine is a substance found in plants in the genus *Aconitum* that is used as an analgesic, anti-inflammatory, and cardiotoxic agent in traditional Chinese medicine (1). Aconitine poisoning is recognised by clinicians in Asia, but it is rarely encountered in the rest of the world. Aconitine and its alkaloids have been predominantly related to cardiotoxicity, although neurotoxicity and gastrointestinal toxicity have also been reported (2). As a result of the particular mechanism of toxicity of aconitine, ventricular arrhythmias (VAs) occur frequently in individuals who consume it (2,3). The management of aconitine poisoning is supportive (2) and follows the general principles of any poisoning treatment (4). Here, we present the case of a male patient with VAs induced by accidental aconitine poisoning.

## CASE REPORT

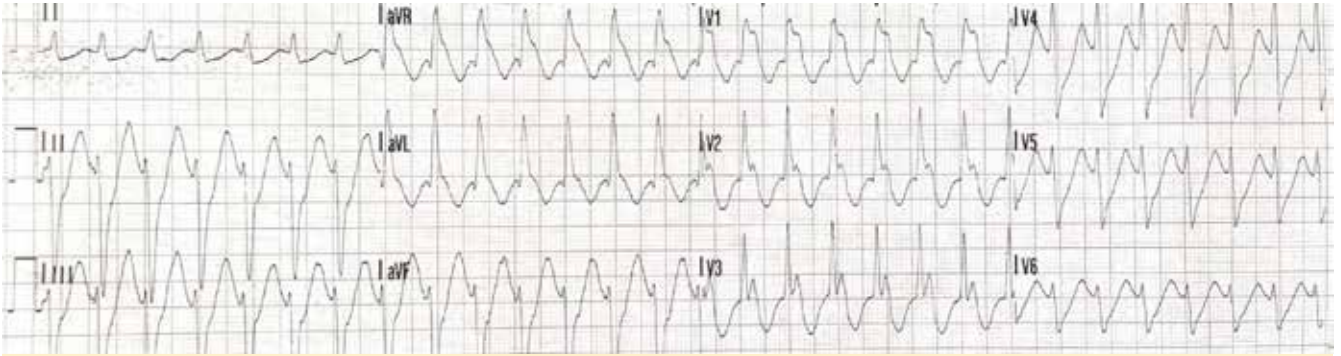
A 43-year-old Chinese male without relevant medical history was admitted to the emergency department (ED) due to acute onset of abdominal pain with nausea and vomiting. His blood pressure on arrival to ED was 120/60 mmHg, with a heart frequency of

160/min and oxygen saturation of 96% on ambient air. His electrocardiogram (ECG) showed a broad complex tachycardia. During the initial minutes of ED admission, the patient became hypotensive. A ventricular tachycardia ensued with torsades de pointes, which promptly developed into ventricular fibrillation (Fig. 1). Cardiopulmonary resuscitation was started, and return of spontaneous circulation followed after a single defibrillation and 2 minutes of cardiopulmonary resuscitation. The initial pulsatile rhythm was ventricular tachycardia (Fig. 2). An unsuccessful synchronized electrical cardioversion was performed. After intravenous administration of amiodarone (300 mg) and magnesium sulphate (4 g), the patient's rhythm converted at first to ventricular bigeminy and soon after to sinus rhythm.

After return of spontaneous circulation, the patient remained hypotensive despite fluid administration (1000 mL of balanced crystalloids) and required a noradrenaline infusion (up to 0.15 µg/kg/min). Supportive treatment with antiemetics and proton pump inhibitors was also administered. He was admitted to the intensive care unit (ICU) 2 h after ED arrival. After ICU admission, the patient's hemodynamic status improved,



**Figure 1.** Ventricular fibrillation in the first minutes of treatment in the emergency department.



**Figure 2.** Ventricular tachycardia after return of spontaneous circulation.

and norepinephrine infusion was discontinued in the first hour of ICU care. Bedside echocardiography revealed a normally functioning left ventricle with no wall motion abnormalities.

Of note, relatives reported the accidental ingestion of a homemade herbal (aconitine) preparation that the patient had been using as a topical painkiller. A mild hypokalaemia and increased troponin levels were recorded in the initial laboratory workup. Due to absent stenocardia, ECG signs for myocardial ischaemia (Fig. 3), and echocardiography abnormalities, we decided against invasive cardiological diagnostics. Given the patient's history and clinical picture, aconitine poisoning was suspected. Active bowel decontamination with activated charcoal and prokinetics was initiated, and intravenous fluids with electrolytes for correction of hypokalaemia were administered. In the first hours of the ICU stay, VAs (Lown 4b) and first-degree atrioventricular block were recorded on ECG. During the next 24 h, arrhythmias and conduction abnormalities gradually resolved (Fig. 3). The patient required a continuous dose of sedatives (dexmedetomidine up to 1 µg/kg/h) due to delirium in the first 12 h.

After 36 h of ICU care, the patient was transferred to a hospital ward with no clinical complaints, and he was hemodynamically and rhythmically stable. His troponin levels normalised. Control echocardiography on day 6 was within the normal range. After 8 days he was discharged without any sequelae. Subsequently, the laboratory report for the urine and blood samples obtained at ICU admission showed aconitine in the

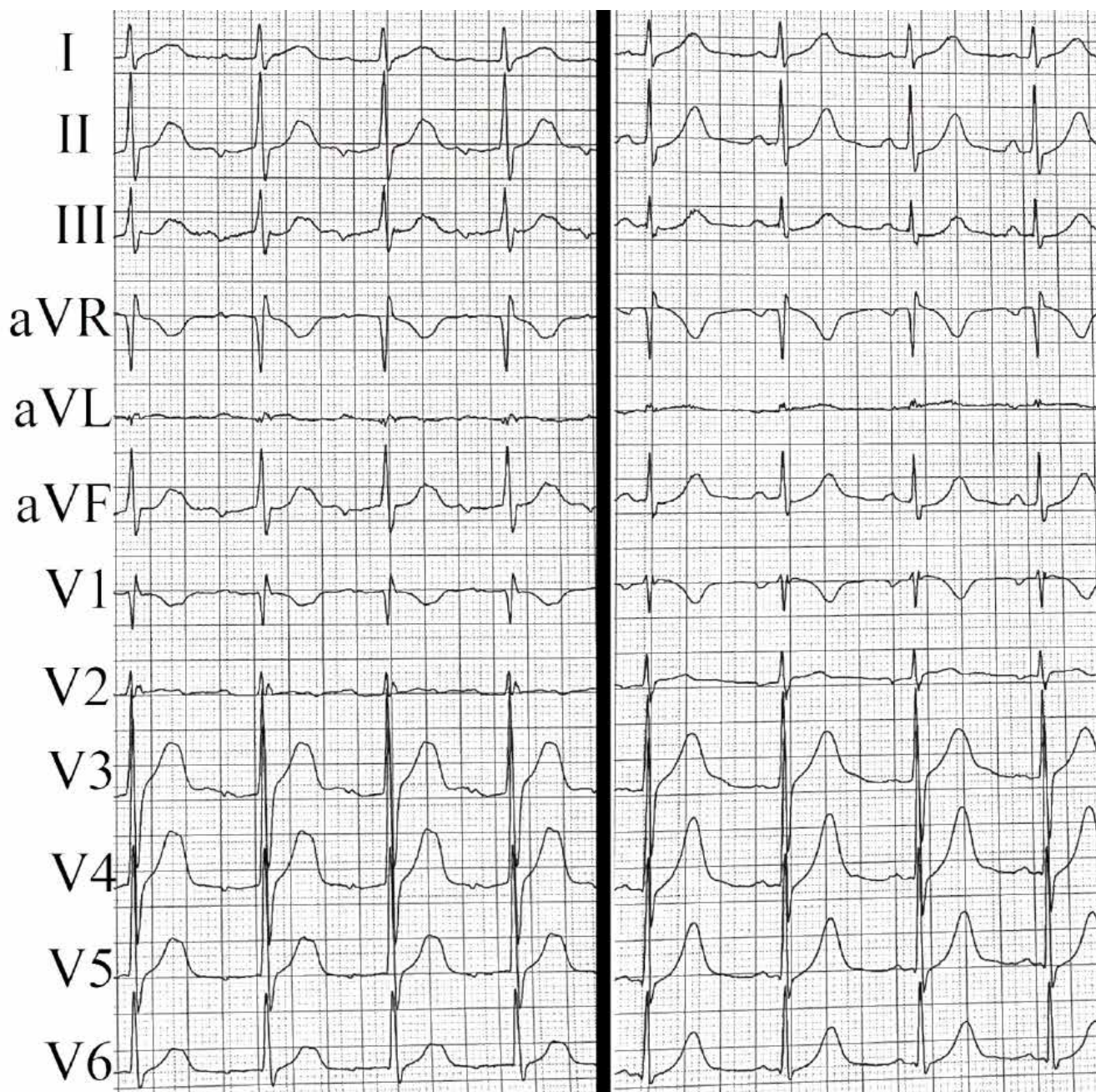
urine analysis. However, the aconitine blood analysis was negative.

## DISCUSSION

Aconitine is the main toxic component present in plants such as *Aconitum carmichaelii*, *A. kusnezoffii*, and *A. napellus*. In traditional Chinese medicine, aconitum plants and roots are frequently used for their efficacy in treating musculoskeletal pain, rheumatic diseases, and abdominal pain (2). They are used only after extensive processing, which is needed to hydrolyse aconite alkaloids into less toxic and non-toxic derivatives. However, use of a larger than recommended dose and inadequate processing increase the risk of poisoning (5). Our case report describes the effects of accidental ingestion of aconitine that the patient was using as a topical painkiller.

Aconitine induces arrhythmias by acting on voltage-dependent sodium channels (NaV channels), predominantly in cardiomyocytes. It binds to the open state NaV channels and prevents them from closing. This results in a prolonged sodium influx and a prolonged action potential (3). The increased intracellular sodium concentration causes further intracellular electrolyte imbalance via malfunctioning Ca<sup>2+</sup>/Na<sup>+</sup> bidirectional exchangers (6). Another potential mechanism of aconitine-induced arrhythmias involves inhibition of potassium channels, which causes further prolongation of the action potential (7). The electrolyte imbalance causes arrhythmias via early and delayed afterdepolarization (3). Researchers have postulated





**Figure 3.** Twelve lead electrocardiograms upon admission to the intensive care unit demonstrating first-degree atrioventricular block (left) and after 24 h of care (right) showing no abnormalities.

that aconitine not only acts on the circulatory organs via the above-described direct action on the heart but also via a central nervous system-induced action, as it was detected in post-mortem analysis of cerebrospinal fluid in patients with aconitine poisoning (3, 8). Clinical symptoms of aconitine poisoning and blood

concentrations of aconitine do not correlate (9). Moritz et al. reported that the half-life of aconitine is 3 h (10). This relatively short half-life could explain the negative aconitine blood analysis result in our case study patient. The reported lethal dose for aconitine is about 1–2 mg (2, 10). Clinical symptoms of aconitine poisoning are

nausea, vomiting, dizziness, palpitation, hypotension, arrhythmias, shock, and coma. Death usually occurs from VAs within the first 24 h after consumption (2, 5). The standard treatment for aconitine poisoning is supportive, as no specific antidote has been identified (2). As in our case, aconitine poisoning can present with a variety of arrhythmias, including ventricular ectopy, ventricular tachycardia, ventricular fibrillation, and torsades de pointes (3). In their review, Coulson et al. presented 65 cases of probable aconitine poisoning resulting in VAs, and they reported that amiodaron and flecainide were more associated with return to sinus rhythm than lidocaine and/or cardioversion (3). However, magnesium sulphate was not reported to efficiently manage VAs (3).

In VAs refractory to conventional treatment, Ren et al. reported that application of extracorporeal life support served as bridge to restore sinus rhythm and allow the toxic alkaloids to be naturally excreted from the circulation (11). In recent reports, researchers presented cases of refractory aconitine-induced arrhythmias treated with left stellate ganglion blockade (12) and intravenous

lipid emulsion (13). These cases emphasise the need for meticulous arrhythmia treatment in patients with aconitine poisoning, and our case highlights the efficacy of amiodaron in treating aconitine-induced VAs (3).

## CONCLUSION

Herein, we present a case of a male patient with severe aconitine poisoning with gastrointestinal and cardiac symptoms in the form of life-threatening VAs and cardiac arrest. To the best of our knowledge, this is one of the first described cases of aconitine-induced VAs in Europe. Clinicians should be aware of potential rare toxicological causes of malignant arrhythmias and consider toxicological screening in otherwise etiologically unexplained sudden cardiac arrest. Our experience also demonstrates how the global spread of alternative treatment methods can delay the diagnosis of potentially life-threatening complications of intoxication.

## REFERENCES:

1. Zhou, W., Liu, H., Qiu, L. Z., Yue, L. X., Zhang, G. J., Deng, H. F., Ni, Y. H., & Gao, Y. (2021). Cardiac efficacy and toxicity of aconitine: A new frontier for the ancient poison. *Medicinal research reviews*, 41(3), 1798–1811. <https://doi.org/10.1002/med.21777>
2. Chan TY. Aconite poisoning. *Clin Toxicol (Phila)*. 2009;47(4):279-285. doi:10.1080/15563650902904407
3. Coulson JM, Caparrotta TM, Thompson JP. The management of ventricular dysrhythmia in aconite poisoning. *Clin Toxicol (Phila)*. 2017;55(5):313-321. doi:10.1080/15563650.2017.1291944
4. Letonja M., & Petrovič D. (2021). Cardiotoxicity and multiorgan system failure caused by valproate poisoning: case report and review of the literature. *Acta Medico-Biotechnica*, 2(02), 52-56. <https://doi.org/10.18690/acta-biomed.23>
5. Bonanno G, Ippolito M, Moscarelli A, et al. Accidental poisoning with Aconitum: Case report and review of the literature. *Clin Case Rep*. 2020;8(4):696-698. Published 2020 Feb 5. doi:10.1002/ccr3.2699
6. Sun GB, Sun H, Meng XB, et al. Aconitine-induced Ca<sup>2+</sup> overload causes arrhythmia and triggers apoptosis through p38 MAPK signaling pathway in rats. *Toxicol Appl Pharmacol*. 2014;279(1):8-22. doi:10.1016/j.taap.2014.05.005
7. Li Y, Tu D, Xiao H, et al. Aconitine blocks HERG and Kv1.5 potassium channels. *J Ethnopharmacol*. 2010;131(1):187-195. doi:10.1016/j.jep.2010.06.025
8. Cho YS, Choi HW, Chun BJ, Moon JM, Na JY. Quantitative analysis of aconitine in body fluids in a case of aconitine poisoning. *Forensic Sci Med Pathol*. 2020;16(2):330-334. doi:10.1007/s12024-019-00211-5
9. Jeon SY, Jeong W, Park JS, et al. Clinical relationship between blood concentration and clinical symptoms in aconitine intoxication. *Am J Emerg Med*. 2021;40:184-187. doi:10.1016/j.ajem.2020.11.005
10. Moritz F, Compagnon P, Kaliszczak IG, Kaliszczak Y, Caliskan V, Girault C. Severe acute poisoning with homemade Aconitum napellus capsules: toxicokinetic and clinical data. *Clin Toxicol (Phila)*. 2005;43(7):873-876. doi:10.1080/15563650500357594
11. Ren B, Wang L, Chen K, Chen L, Wang H. Case Report: Venoarterial Extracorporeal Membrane Oxygenation Support for Caowu-Induced Cardiac Arrest. *Front Med (Lausanne)*. 2021;8:731163. Published 2021 Nov 3. doi:10.3389/fmed.2021.731163
12. Ichikawa Y, Matsumoto S, Fujinaka W, Takatori M, Nishioka K, Namera A. Left Stellate Ganglion Blockade for Refractory Ventricular Arrhythmias With Aconitine Poisoning: A Case Report. *A A Pract*. 2023;17(2):e01666. Published 2023 Feb 20. doi:10.1213/XAA.0000000000001666
13. Han S, Lim H, Noh H. Intravenous lipid emulsion therapy for cardiac arrest and refractory ventricular tachycardia due to multiple herb intoxication. *Clin Exp Emerg Med*. 2019;6(4):366-369. doi:10.15441/ceem.18.078