

# Hibridna oskrba zloma podlahti pri mladostniku: reprezentacija primera in pregled literature

## Hybrid fixation for repair of dual forearm fractures of adolescent patients: A case report and literature review

Avtor / Author

Ustanova / Institute

Igor Movrin<sup>1</sup>

<sup>1</sup>Univerzitetni klinični center Maribor, Klinika za kirurgijo, Oddelek za travmatologijo, Maribor, Slovenija; <sup>2</sup>Univerza v Mariboru, Medicinska fakulteta, Maribor, Slovenija;

<sup>1</sup>University Medical Centre Maribor, University Division of Surgery, Department of Traumatology, Maribor, Slovenia; <sup>2</sup>University of Maribor, Faculty of Medicine, Maribor, Slovenia;

### Ključne besede:

zlom podlahti, hibridna fiksacija, elastična titanijeva intramedularna žica, odprta naravna in notranja učvstitev zloma

### Key words:

forearm fractures, hybrid fixation, elastic stable intramedullary nailing (ESIN), open reduction in internal fixation

### Članek prispel / Received

20. 7. 2023

### Članek sprejet / Accepted

22. 3. 2024

### Naslov za dopisovanje /

#### Correspondence

Doc. dr. Igor Movrin, dr. med.  
 Univerzitetni klinični center Maribor  
 Klinika za kirurgijo, Oddelek za  
 travmatologijo, Maribor, Slovenija  
 igor.movrin@ukc-mb.si

### Izvleček

**Namen:** Namen prispevka je reprezentacija primera in definiranje hibridne fiksacije kot ustrezne alternative v zdravljenju zlomov obeh kosti podlahti pri mladostniku.

#### Reprezentacija primera:

Obravnavamo primer 11-letnega pacienta moškega spola, ki je pri padcu na trampolinu utrpel zlom obeh kosti desne podlahti. V splošni narkozi je bila opravljena zaprta repozicija zloma in intramedularna fiksacija zloma koželjnice z elastično titanijevo žico. Nestabilni zlom podlahtnice je bil odprto naravnan in v anatomskega položaju fiksiran s ploščo in vijaki. Na kontrolnem pregledu tri mesece po operaciji je pacient izkazal polno gibljivost desne podlahti, zlom je bil zaceljen v dobrem položaju, drugih težav ni bilo.

### Abstract

**Purpose:** To assess hybrid fixation as an alternative option for repair of dual forearm fractures of adolescent patients.

**Case presentation:** An 11-year-old boy presented with trauma to his right forearm resulting from playing on a trampoline. X-ray examinations confirmed fractures of both the right ulna and radius. Closed reduction and internal ESIN (elastic stable intramedullary nailing) fixation was selected for repair of the radius. Closed reduction of the ulnar fracture was unsuccessful, thus open reduction was performed. However, due to instability of the ulnar fracture after open reduction, internal plate fixation of the ulna was selected. At 3 months after surgery, the patient demonstrated full range of motion with no pain.

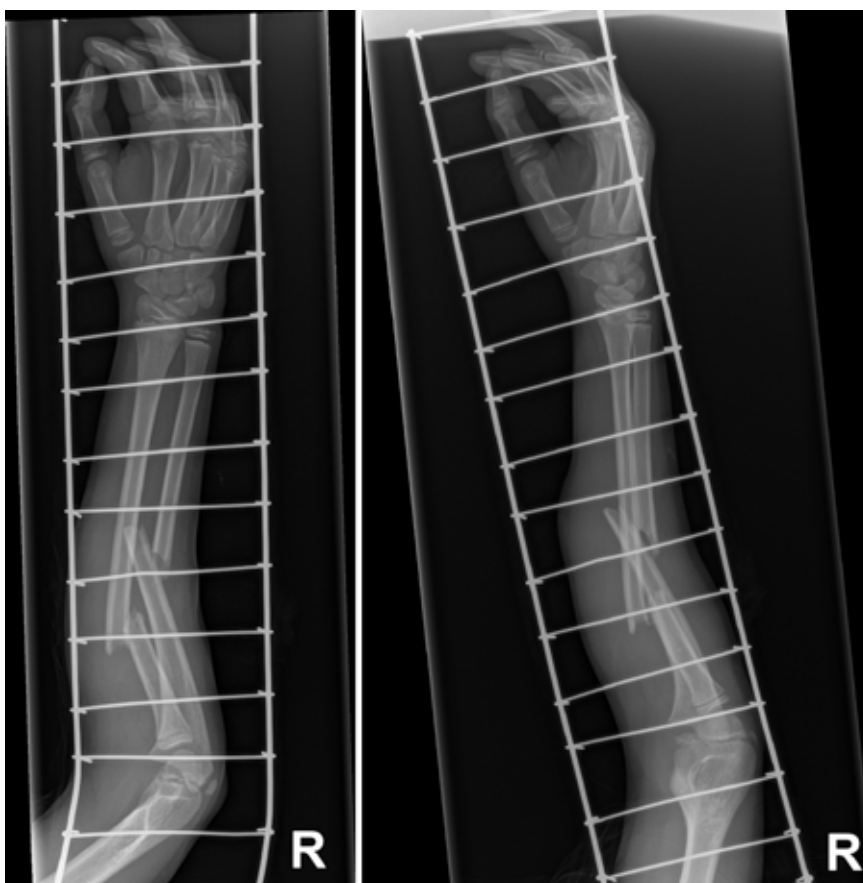
## INTRODUCTION

Forearm fractures are common injuries of children. Dual fractures of both the ulna and radius account for 3.4% of all fractures and 26% of all upper limb fractures of pediatric patients (1). Most fractures of the forearm of children younger than 10 years can be effectively repaired by closed reduction and casting because of the considerable potential for bone remodeling of this age group (2). Although casting remains a viable treatment option for children aged 10 years and older, the criteria for acceptable closed reduction in this group is more stringent because successful bone remodeling decreases with age (3). The most common surgical interventions for repair of forearm fractures of adolescent patients include elastic stable intramedullary nailing (ESIN) and open reduction with plate-screw fixation. Comparatively, the ESIN method can achieve superior cosmesis due to less stripping of the bone periosteum and relatively small surgical incisions (4, 5). Plate-screw fixation provides anatomic reduction and more stable fixation, with almost complete restoration of forearm rotational movements (6). However, this approach is limited by extensive soft tissue dissection, periosteal damage during plate fixation, and increased risks of re-fracture after plate removal (7). The hybrid fixation method involves fixation of the radius or ulna with the use of ESIN, while plate-screw fixation is used for the other bone to achieve anatomic reduction. The hybrid fixation method reduces the extent of intraoperative soft tissue dissection and the potential risk of re-fracture after implant removal (8). We report a case of an 11-year old boy who presented with fractures of both bones of the forearm who underwent closed reduction and

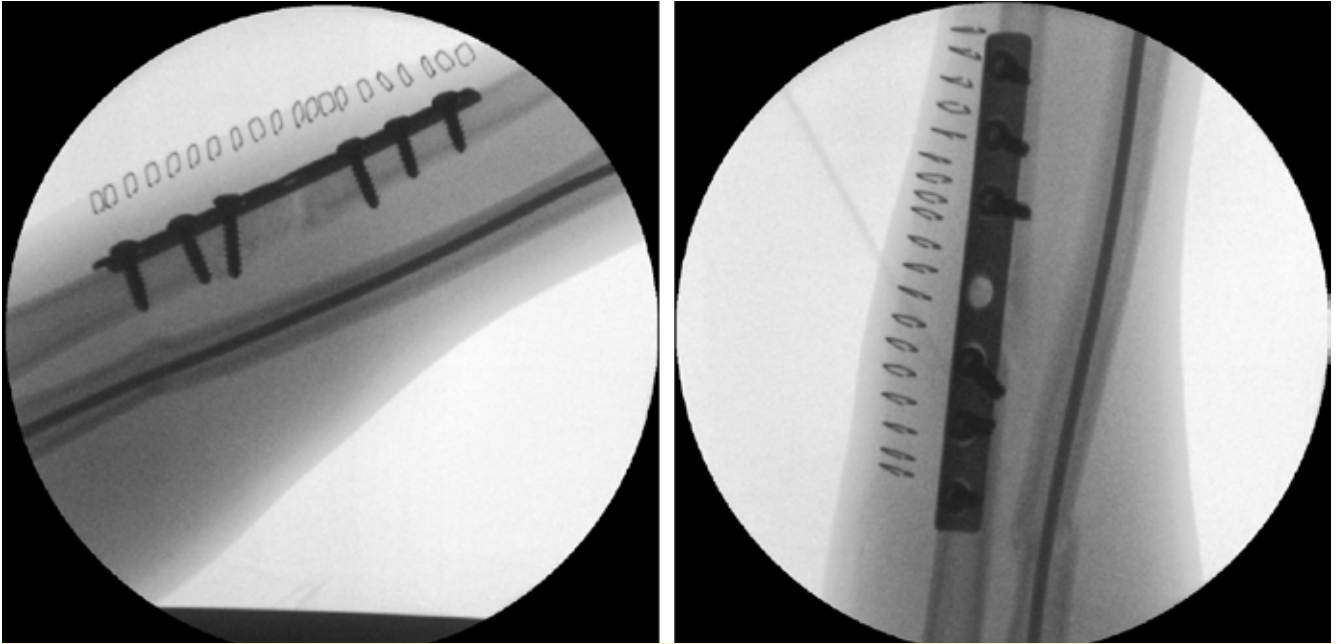
internal ESIN fixation of the radius in addition to open reduction and internal plate fixation of the ulna in an attempt to decrease the rate of complications and improve clinical efficiency.

## CASE REPORT

An otherwise healthy 11-year-old boy presented to our Emergency Department with trauma to his right forearm that occurred while playing on a trampoline. After the accident, he was unable to move his right arm because of extreme pain. A physical examination confirmed swelling and deformity of the right forearm with restricted motion. An X-ray examination confirmed fractures to both the right ulna and radius (Fig. 1).



**Figure 1.** Anteroposterior (left) and lateral (right) primary radiographs of the fracture showing fractures at the middle third of the radial and ulnar shafts.



**Figure 2.** Anteroposterior (left) and lateral (right) intraoperative radiographs demonstrating good alignment and no diastases at the fracture site.

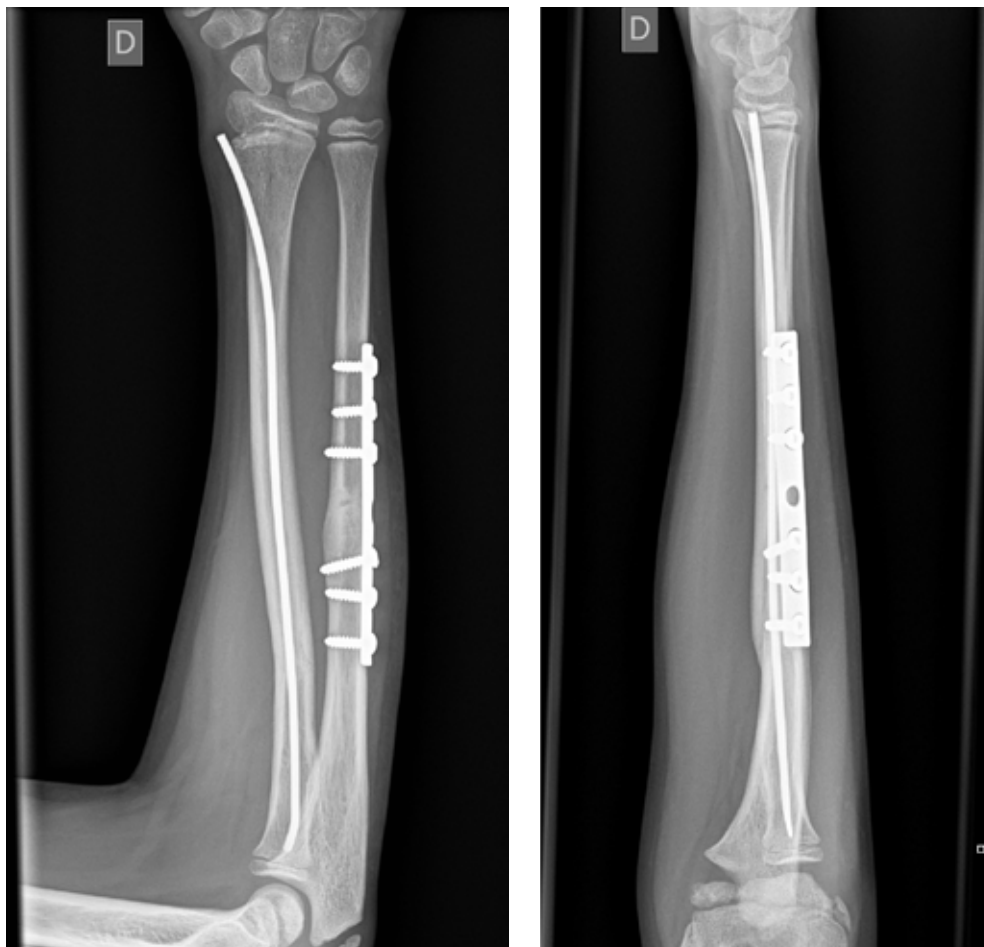
Potential injuries to the nerves and blood vessels of the patient were evaluated upon presentation to the Emergency Department and before surgery. The patient underwent closed reduction and internal ESIN fixation of the radius (Titanium Elastic Nail (TEN™) System; 2.5 mm; Synthes GmbH, Oberdorf, Switzerland). Closed reduction of the ulnar fracture was unsuccessful, thus open reduction was performed. Because the ulnar fracture after open reduction was unstable, internal plate fixation of the ulna was selected (One-third Tubular Plate; 3.5-mm screws with collar; 7 holes; Synthes GmbH). Intraoperative radiography showed good alignment and no diastases of the fracture site (Fig. 2). The fractures were stabilized with a long arm cast and he was discharged on postoperative day 2.

After 2 weeks, the cast and sutures were removed at our Outpatient Clinic. The patient, a very active boy, was provided with a protective short arm cast that was removed by his parents at 4 weeks after surgery, as scheduled. The results of a follow-up examination at 6 weeks after surgery showed that the patient regained full range of motion of the affected limb and reported little pain. Radiography showed good alignment and healing

of both forearm fractures. During the last follow-up at 3 months after surgery, the patient demonstrated full range of motion with no pain or apparent neurovascular injury. Radiography demonstrated union of both forearm fractures (Fig. 3). The implant was scheduled for removal at 6 months after surgery.

## DISCUSSION

Although there is no general consensus, surgical management with ESIN fixation for dual fractures of the ulna and radius is becoming more popular for adolescent patients (9, 10). The advantages of ESIN fixation include relatively small incisions, shorter surgical duration, and minimal dissection at the fracture line (4). Nonetheless, WSIN fixation is associated with various complications, such as delayed union, pseudoarthrosis of the ulna, infection, skin irritation caused by the implant, migration or failure of the implant, tendon injury, and compartment syndrome (9). Ogonda et al. (11) reported higher frequencies of delayed union and pseudoarthrosis after anterograde ESIN fixation



**Figure 3.** Anteroposterior (left) and lateral (right) radiographs showing union of the radius and ulna at 3 months after surgery.

of the ulna due to compression of the fracture line as compared to retrograde ESIN fixation of the radius. Although two separate incisions revealing the fractures, adequate reduction, and appropriate implant placement are essential for open reduction and internal fixation, this technique can achieve good functional results by reconstructing the radial bow, while providing axial and rotational control of the reduction to regain range of motion of the forearm.

The ulna plays a greater role in maintaining the stability of the forearm than the radius, especially during buckling and torsional stress (12). Fixation of the ulnar plate provides better stability than the ESIN method. Therefore, restoration of the original function of the ulna is necessary to rebuild forearm stability and allows the

radius to achieve greater antirotation performance (13). This case report confirms that hybrid plate fixation with ESIN is suitable for repair of dual forearm fractures of children and adolescents (14).

## CONCLUSION

Hybrid fixation with ESIN of the radius combined with conventional plating of the ulna is a suitable option to help reduce the non-union rate and restore rotational control of the forearm, while reducing the extent of soft tissue dissection. We recommend this method for repair of dual forearm fractures of pediatric patients.

## REFERENCES

1. Landin LA. Fracture patterns in children. Analysis of 8,682 fractures with special reference to incidence, etiology and secular changes in a Swedish urban population 1950-1979. *Acta Orthop Scand Suppl. Acta Orthop Scand Suppl*; 1983;202:1-109.
2. Franklin CC, Robinson J, Noonan K, Flynn JM. Evidence-based medicine: management of pediatric forearm fractures. *J Pediatr Orthop*. 2012 Sep;32 Suppl 2:S131-4.
3. Cai L, Wang J, Du S, Zhu S, Wang T, Lu D, et al. Comparison of Hybrid Fixation to Dual Plating for Both-Bone Forearm Fractures in Older Children. *American Journal of Therapeutics*. 2016 Nov;23(6):e1391-e1396.
4. Kang S-N, Mangwani J, Ramachandran M, Paterson JMH, Barry M. Elastic intramedullary nailing of paediatric fractures of the forearm: a decade of experience in a teaching hospital in the United Kingdom. *J Bone Joint Surg Br. Bone & Joint*; 2011 Feb;93(2):262-5.
5. Patel A, Li L, Anand A. Systematic review: functional outcomes and complications of intramedullary nailing versus plate fixation for both-bone diaphyseal forearm fractures in children. *Injury*. 2014 Aug;45(8):1135-43.
6. Shah AS, Lesniak BP, Wolter TD, Caird MS, Farley FA, Vander Have KL. Stabilization of adolescent both-bone forearm fractures: a comparison of intramedullary nailing versus open reduction and internal fixation. *J Orthop Trauma*. 2010 Jul;24(7):440-7.
7. Westacott DJ, Jordan RW, Cooke SJ. Functional outcome following intramedullary nailing or plate and screw fixation of paediatric diaphyseal forearm fractures: a systematic review. *J Child Orthop. SAGE PublicationsSage UK: London, England*; 2012 Mar;6(1):75-80.
8. Zeybek H, Akti S. Comparison of Three Different Surgical Fixation Techniques in Pediatric Forearm Double Fractures. *Cureus*. 2021 Aug;13(8):e16931.
9. Jubel A, Andermahr J, Isenberg J, Issavand A, Prokop A, Rehm KE. Outcomes and complications of elastic stable intramedullary nailing for forearm fractures in children. *J Pediatr Orthop B*. 2005 Sep;14(5):375-80.
10. Du S-H, Feng Y-Z, Huang Y-X, Guo X-S, Xia D-D. Comparison of Pediatric Forearm Fracture Fixation Between Single- and Double-Elastic Stable Intramedullary Nailing. *Am J Ther*. 2016;23(3):e730-6.
11. Ogonda L, Wong-Chung J, Wray R, Canavan B. Delayed union and non-union of the ulna following intramedullary nailing in children. *J Pediatr Orthop B*. 2004 Sep;13(5):330-3.
12. Salvi AE. Forearm diaphyseal fractures: which bone to synthesize first? *Orthopedics*. 2006 Aug;29(8):669-71-discussion671.
13. Elhalawany AS, Afifi A, Anbar A, Galal S. Hybrid fixation for adolescent both-bones diaphyseal forearm fractures: Preliminary results of a prospective cohort study. *Journal of Clinical Orthopaedics and Trauma*. 2020 Feb;11:S46-S50.
14. Bai X, Liu Z, Chen W, Wang B. Hybrid fixation with ESIN for both bone forearm fractures in adults: A case report and literature review. *Front Surg*. 2022;9:949727.