

Tansaksilarni TAVI – poročilo prvih primerov

Transaxillary transcatheter aortic valve implantation (TAVI)—our first case reports

Avtor / Author

Nina Glavnik Poznič¹, Igor Balevski^{1,5}, Boris Robič², Jure Fluher³, Jože Kučič^{4,6}, Vojko Kanič^{1,5}

Ustanova / Institute

¹Univerzitetni klinični center Maribor, Oddelek za kardiologijo in angiologijo, Maribor, Slovenija; ²Univerzitetni klinični center Maribor, Oddelek za kardiokirurgijo, Maribor, Slovenija; ³Univerzitetni klinični center Maribor, Oddelek za intenzivno interno medicino, Maribor, Slovenija; ⁴Univerzitetni klinični center Maribor, Oddelek za anesteziologijo, intenzivno terapijo in terapijo bolečin, Maribor, Slovenija; ⁵Univerza v Mariboru, Medicinska fakulteta, Katedra za interno medicino, Maribor, Slovenija; ⁶Univerza v Mariboru, Medicinska fakulteta, Katedra za anesteziologijo in reanimatologijo, Maribor, Slovenija;

¹University Clinical Centre Maribor, Department for Cardiology and Angiology, Maribor, Slovenia; ²University Clinical Centre Maribor Department for Cardiosurgery, Maribor, Slovenia; ³University Clinical Centre Maribor, Department for Internal Intensive Medicine, Maribor, Slovenia; ⁴University Clinical Centre Maribor, Department for Anesthesiology, Intensive Care and Pain Management, Maribor, Slovenia; ⁵University of Maribor, Faculty of Medicine, Department for Internal Medicine, Maribor, Slovenia; ⁶University of Maribor, Faculty of Medicine, Department for Anesthesiology and reanimation, Maribor, Slovenia;

Ključne besede:

aortna stenoza, TAVI, aksilarna arterija, periferna arterijska bolezen, perkutano

Key words:

aortic stenosis, transcatheter aortic valve implantation (TAVI), axillary artery, peripheral artery disease, percutaneous

Članek prispel / Received

17. 10. 2022

Članek sprejet / Accepted

17. 3. 2023

Naslov za dopisovanje /

Correspondence

Nina Glavnik Poznič
nina_glavnik@yahoo.com

Izvleček

V zadnjih desetletjih se spoprijemamo s porastom števila bolnikov s hudo aortno stenozo. Zaradi napredka tehnike in izkušenj pa se starostna meja za vgraditev aortne zaklopke po dimeljski (femoralni) arteriji – femoralni TAVI (transcatheter aortic valve implantation) postopoma znižuje. Bolniki z aortno stenozo imajo pogosto periferno arterijsko bolezen, pomembne zožitve na pelvičnih arterijah pa lahko onemogočijo perkutani transfemoralni pristop (brez kirurške preparacije). V primeru visokega tveganja za klasično kirurško menjavo zaklopke razvijajo nove metode žilnega pristopa za TAVI. V Mari-

Abstract

In the past decade, the incidence of severe aortic stenosis has been high because of population aging. Guidelines have recommended transfemoral transcatheter aortic valve implantation (TAVI) for a wider patient population, because of technical improvements and increased experience among physicians. Peripheral artery disease often accompanies aortic stenosis and is an important contraindication for transfemoral TAVI. Currently, new access sites for TAVI are used in cases with high surgical risk. We performed the first two axillary TAVI procedures

boru smo opravili dva posega po pazdušni (aksilarni) arteriji. Primera bomo v članku tudi predstavili.

at our institution. The two patients are described in this case report.

INTRODUCTION

Aortic stenosis is the most common cause of heart failure in industrialized countries. Because of its degenerative nature, its incidence increases with age. Patients usually present with dyspnea, congestive heart failure, or syncope. Symptomatic severe aortic stenosis is a fatal disease with a mortality rate of 80% within 5 years. (1).

In older patients, surgical replacement is usually associated with a higher risk of perioperative complications and death. Therefore, percutaneous techniques are currently recommended as the first-choice therapy (2).

Minimally invasive aortic valve implantation was first introduced by cardiac surgeons with transapical or transaortic valve implantation. To avoid thoracotomy, a transarterial procedure was developed to implant the prosthetic valve via the femoral artery. After downsizing of the delivery system and the development of new techniques to close the large punctures in the access sites (3), transfemoral transcatheter aortic valve implantation (TAVI) can now be performed in a “minimalistic” manner in patients under local anesthesia and conscious sedation (4). This strategy substantially shortens hospital stays by enabling early patient mobilization and resulting in fewer hospital-acquired infections (5).

Post procedural rehabilitation may be prolonged by the development of AV (atrioventricular) block the need for a permanent pacemaker. According to patient specific factors, patients need a pacemaker in as many as 20% of cases.

All access strategies depend on the patient’s anatomy. The straightest and largest vessel without excessive calcification and tortuosity is preferred. In cases of severe peripheral arterial disease with unfavorable access for the transfemoral approach, other vascular routes have been introduced.

Beyond the femoral approach, TAVI can also be performed via other major arteries. Because of the possibility of performing a completely percutaneous procedure, we chose transaxillary TAVI in two patients

who were not candidates for transfemoral TAVI. These two cases are presented in the following section.

CASE REPORTS

In both patients, surgical aortic valve replacement was rejected because of comorbidities and the high perioperative risk. Because of severe peripheral artery disease, the vascular lumen was too small for transfemoral TAVI. Computed tomography angiography (CTA) of the upper extremities in both patients indicated a good left axillary access site; acceptable left subclavian artery exit angle; and adequate aortic annulus, aortic sinus, and coronary take-off anatomy.

After an extensive literature review, we decided to perform the first procedures under general anesthesia. Considering the proctor’s advice, we surgically prepared the puncture site to avoid potential problems and complications with percutaneous closure in the first cases.

A 76-year-old woman was admitted to hospital care for syncope and progressive dyspnea. The procedure was technically challenging because the ascending aorta was horizontal, thus making passage of the delivery system through the native valve difficult. After predilation and careful adjustment, the TAVI valve was successfully implanted. Despite the use of an optimal implantation position, the patient developed transient complete AV block and had a permanent pacemaker implanted after 3 days. After 1 week, she was discharged in good condition. An 83-year-old man was electively referred for TAVI. The left subclavian and left carotid arteries were severely calcified, particularly their outlets. Notably, the subclavian artery was more difficult to pass than expected, but passage of the valve was achieved through use of a different stiffer introducer wire. The patient developed neurologic symptoms in the first 12 hours after

the procedure and required a stent for left carotid stenosis. We hypothesized that cerebral hypoperfusion was caused by the prolonged pulseless state during valve implantation (due to high-frequency temporal pacing) and excessive manipulation during passage through the subclavian artery (near the exit of the left carotid artery). The patient was discharged with mild neurological sequelae.

Both patients reported good health at follow-up. Echocardiography after six months showed good function of the TAVI prosthetic valve.

DISCUSSION

TAVI can be performed via alternative routes. In fact, the first TAVI in humans was performed via the femoral vein with transseptal puncture in a retrograde fashion. Currently, this method is rarely used, because the delivery systems are very rigid and have been optimized to provide sufficient thrust via the transfemoral route. Transaortic and transapical procedures represent a step backward from the original idea of percutaneous access, because they require a small thoracotomy, surgical access preparation, and hemostasis. Transapical procedures are rarely used because of their relatively higher bleeding complication rates. In the quest to achieve a completely percutaneous approach, transaortic access is now being replaced by transcarotid and transaxillary access. The transcarotid approach has been introduced in recent years. This approach requires at least some surgical vascular preparation and anesthesia, and is also uncomfortable for the operator (6). The transaxillary approach is the most recently described approach to the peripheral arteries. This approach involves a more ergonomic set up for the procedure and can be performed completely percutaneously, but closing the puncture site can sometimes be challenging (7). Another completely percutaneous approach is the transcaval approach. This approach is rarely used because it requires specialized equipment, thus increasing the overall cost of the procedure (8).

Femoral arterial access is unsuitable for large bore procedures in 13–20% of cases, owing to extensive atherosclerosis from previous procedures such as bypass surgery, patching, or endovascular treatment. In contrast

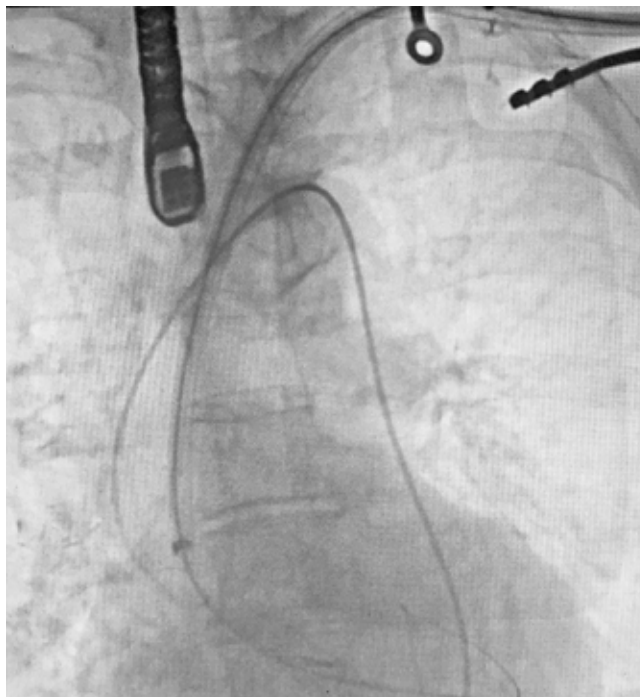


Figure 1: Transaxillary TAVI with surgical cut-down of access site. Guidewire in left ventricle with TAVI introduction sheath to level of native aortic valve, secondary arterial access from femoral artery (pigtail catheter tip at aortic valve), temporary pacemaker lead in right ventricle, TEE probe.

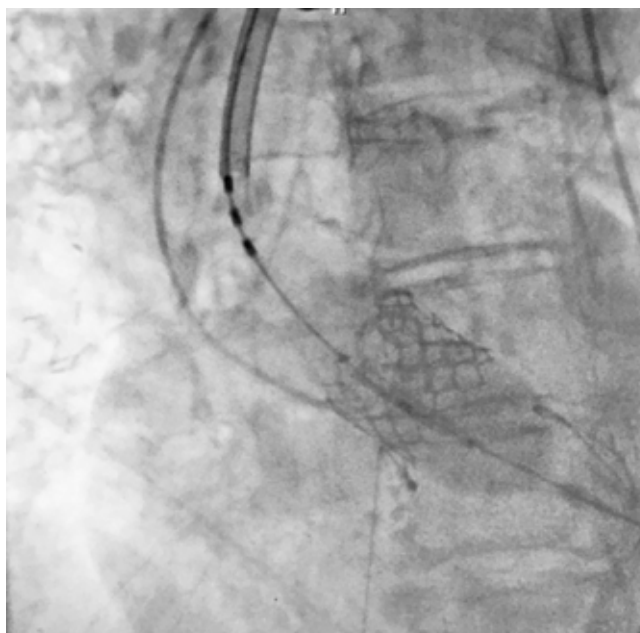


Figure 2: Balloon inflation of TAVI valve with delivery system on guidewire in left ventricle, pigtail catheter as marker at level of native aortic valve, temporary pacemaker lead in right ventricle during rapid pacing.

to the femoral artery, the axillary artery is generally spared from extensive atherosclerotic disease. The axillary artery was originally used for coronary interventions or placement of short-term mechanical circulatory systems (9). Percutaneous transaxillary procedure is traditionally performed through a surgical incision to achieve more precise puncture and hemostasis (Fig. 3). Controlled hemostasis is also the most important advantage of surgical access compared with percutaneous access.

The tranaxillary approach has some potential disadvantages and warrants several considerations. The axillary artery is an elastic artery that is susceptible to dissection and rupture. CT may reveal excessive tortuosity or calcification, which may limit the use of large devices and may lead to dissection or embolization of calcium. LIMA graft is a contraindication for left axillary access, and large tubes may impair flow to the revascularized area. Pacemakers or defibrillators may also interfere with

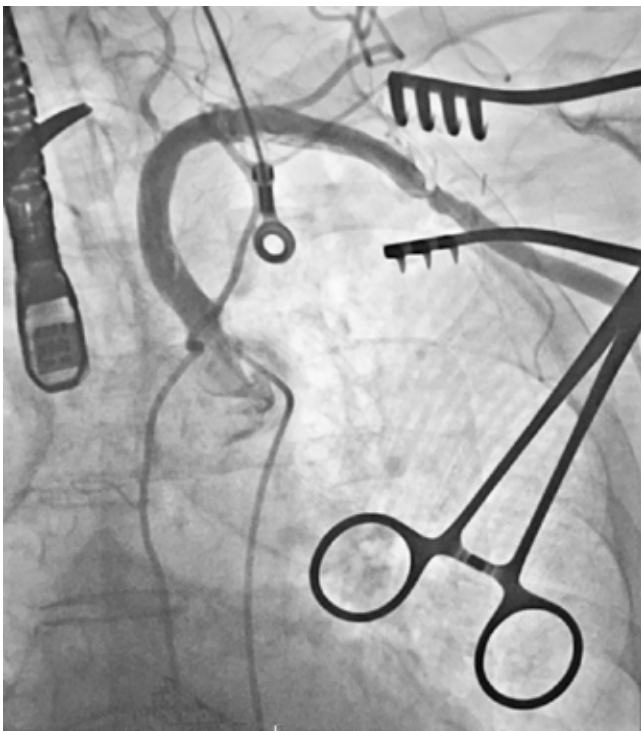


Figure 3: Control left subclavian angiography after surgical closure of access site.

puncture at a shallow angle. Special attention should be paid to the aorto-subclavian angle of descent. An excessively steep exit angle may make handling of the cable and delivery system difficult (8).

Given the relatively short distance from the puncture site to the aortic valve, transaxillary TAVI is technically challenging (Fig. 1). Traversing the valve usually requires deep sheath insertion and its retrieval before valve implantation. These maneuvers can both mobilize calcium in the subclavian artery and cause direct interaction of sheath with the diseased aortic valve. The procedure requires careful periprocedural heparin anticoagulation, and monitoring of neurologic status and hemodynamics after admission to the ward. Compared with transfemoral TAVI, transaxillary TAVI has a higher stroke rate (10)

In our cases, we encountered most of the above challenges. The first case had a low aorta-annular angle, which is rarely referred to as horizontal aorta in the literature (Fig. 2). This angle is unfavorable because advancement of the sheath and system to the level of the aortic valve requires more forceful movement. Rapid forward motion may cause sheath and delivery system to slip through the valve and perforate the coronary sinus or left ventricle. To achieve good positioning of the TAVI valve, special attention must be paid to good operator coordination. In the case of optimal valve position, heart block is usually caused by native valve calcium that has been pushed to the aortic anulus side and damage nearby conduction system.

In general, TAVI practice using alternative non-femoral approaches differs across countries. Long-term observational studies have shown that the transfemoral approach is the gold standard for TAVI. The number of patients ineligible because of atherosclerosis can be decreased by periprocedural lesion modification techniques such as lithotripsy. Other approaches are possible but require additional device optimization and operator skills. These modalities are more challenging for teams such as ours, because cardiologists are not routinely involved in percutaneous procedures on peripheral arteries. According to best clinical practice, TAVI centers should choose one additional approach, because the number of these procedures is usually small.

CONCLUSION

New percutaneous techniques and procedures in the field of structural heart disease are rapidly evolving. Although both procedures were challenging, we were able to successfully implant both valves. However, the procedure requires a multidisciplinary approach (TAVI team, cardiology department team, anesthesia team,

and cardiac surgery team) to support the vision of state-of-the-art care for these vulnerable patients. Moreover, these procedures were successfully performed despite the unfavorable COVID-19 situation and travel restrictions, and collaboration was key to success.

REFERENCES

1. Horstkotte D, Loogen F. The natural history of aortic valve stenosis. *Eur Heart J.* 1988 Apr 1;9(suppl_E):57–64.
2. Vahanian A, Praz F, Milojevic M, Baldus S, Bauersachs J, Capodanno D, et al. 2021 ESC/EACTS Guidelines for the management of valvular heart disease [Internet]. *EuroIntervention.* [cited 2022 Jun 2]. Available from: <https://eurointervention.pconline.com/article/2021-esc-eacts-guidelines-for-the-management-of-valvular-heart-disease>
3. Costa G, Valvo R, Picci A, Criscione E, Reddavid C, Motta S, et al. An upfront combined strategy for endovascular haemostasis in transfemoral transcatheter aortic valve implantation [Internet]. *EuroIntervention.* [cited 2022 Sep 15]. Available from: <https://eurointervention.pconline.com/article/effectiveness-of-upfront-combined-strategy-for-endovascular-hemostasis-in-transfemoral-transcatheter-aortic-valve-implantation>
4. Minimalist Approaches to TAVR: Options and Implications [Internet]. American College of Cardiology. [cited 2022 Aug 13]. Available from: <https://www.acc.org/latest-in-cardiology/articles/2020/03/31/09/48/http%3a%2f%2fwww.acc.org%2flatest-in-cardiology%2farticles%2f2020%2f03%2f31%2f09%2f48%2fminimalist-approaches-to-tavr>
5. Siontis GCM, Overtchouk P, Cahill TJ, Modine T, Prendergast B, Praz F, et al. Transcatheter aortic valve implantation vs. surgical aortic valve replacement for treatment of symptomatic severe aortic stenosis: an updated meta-analysis. *Eur Heart J.* 2019 Oct 7;40(38):3143–53.
6. Publishing ED&. Percutaneous interventional cardiovascular medicine: The PCR-EAPCI Textbook [Internet]. [cited 2022 Jun 2]. Available from: <https://www.pconline.com/eurointervention/textbook/pcr-textbook/table-of-contents/>
7. Seto AH, Estep JD, Tayal R, Tsai S, Messenger JC, Alraies MC, et al. SCAI Position Statement on Best Practices for Percutaneous Axillary Arterial Access and Training. *J Soc Cardiovasc Angiogr Interv.* 2022 May 1;1(3):100041.
8. Biasco L, Ferrari E, Pedrazzini G, Faletra F, Moccetti T, Petracca F, et al. Access Sites for TAVI: Patient Selection Criteria, Technical Aspects, and Outcomes. *Front Cardiovasc Med.* 2018 Jul 17;5:88.
9. Harloff MT, Percy ED, Hirji SA, Yazdchi F, Shim H, Chowdhury M, et al. A step-by-step guide to trans-axillary transcatheter aortic valve replacement. *Ann Cardiothorac Surg.* 2020 Nov;9(6):510–21.
10. Faroux L, Junquera L, Mohammadi S, Del Val D, Muntané-Carol G, Alperi A, et al. Femoral Versus Nonfemoral Subclavian/Carotid Arterial Access Route for Transcatheter Aortic Valve Replacement: A Systematic Review and Meta-Analysis. *J Am Heart Assoc.* 2020 Oct 6;9(19):e017460.

