

# Indikatorji strain pri oceni sistolične miokardialne funkcije pri fantku s hipertrofično kardiomiopatijo: opis primera

## Strain indicators in the assessment of systolic myocardial function in a boy with hypertrophic cardiomyopathy: a case report

Avtor / Author

Ustanova / Institute

Nadezhda Chernykh<sup>1</sup>, Alla Tarasova<sup>2</sup>, Olga Groznova<sup>3</sup>

<sup>1</sup>Univerza v Mariboru, Medicinska fakulteta, Maribor, Slovenija; <sup>2</sup>Russian Medical Academy Continuous Professional Education Ministry of Health of the Russian Federation, Moscow, Russia; <sup>3</sup>Academician Yu. E. Veltishchev Research Clinical Institute of Pediatrics, N. I. Pirogov Russian National Research Medical University, Ministry of Health of the Russian Federation, , Moscow, Russia

<sup>1</sup>University Medical Centre Maribor, Division of Gynecology and Perinatology, Department for Gynecologic and Breast Oncology, Maribor, Slovenia; <sup>2</sup>Russian Medical Academy Continuous Professional Education Ministry of Health of the Russian Federation, Moscow, Russia; <sup>3</sup>Academician Yu. E. Veltishchev Research Clinical Institute of Pediatrics, N. I. Pirogov Russian National Research Medical University, Ministry of Health of the Russian Federation, , Moscow, Russia

### Ključne besede:

2D speckle-tracking, strain, hipertrofična kardiomiopatija, zgodnje zdravljenje, otrok

### Key words:

2D speckle-tracking, strain, hypertrophic cardiomyopathy, early treatment, children

### Članek prispel / Received

13. 7. 2018

### Članek sprejet / Accepted

10. 11. 2019

### Naslov za dopisovanje /

#### Correspondence

Nadezhda Chernykh,

Erazmus študentka na MF UM

v letu 2018

Telefon +7(917) 3317861

E-pošta: chernykh-nauka@mail.ru

### Izvleček

**Namen:** Članek predstavlja zanimiv klinični primer 14-letnega fanta s hipertrofično kardiomiopatijo (HCM). Vrednosti ejekcijske frakcije (EF) in "shortening" frakcije levega ventrikla so pri otrocih s hipertrofično kardiomiopatijo dolgo časa v sprejemljivih okvirjih. Zaznava zmanjšanja segmetalne miokardialne kontraktlnosti na začetku bolezni predstavlja diagnostično težavo.

**Metode:** Predstavljene so klinične lastnosti bolnika, rezultati študij in analiza obremenitve miokardija levega ventrikla v "2D speckle-tracking" nastavitvi z ehokardiografsko študijo.

**Rezultati:** Ugotovljeno je bilo zmanjšanje vrednosti v indikatorjih obremenitve v anterioseptalnem, anteriornem in anterolateralnem segment miokardija

### Abstract

**Purpose:** This article is about an unusual clinical case of a 14-year-old boy with hypertrophic cardiomyopathy (HCM). Ejection fraction (EF) and shortening fraction (FS) of the left ventricle in children with HCM remain within a normal range for an extended period of time. Therefore, detection of a decrease in segmental myocardial contractility at the initial stage of the disease presents a diagnostic problem.

**Methods:** The clinical characteristics of the patient, study results, and analysis of the left ventricular myocardial strain using 2D speckle-tracking mode in an echocardiographic examination are presented.

**Results:** A decrease in strain indicators in the anterioseptal, anterior, and

levega ventrikla ter kompenzatorno zvišanje vrednosti v kontralateralnih segmentih. Ugotovljene vrednosti so služile kot indikacija za začetek zdravljenja.

**Zaključek:** Zmanjšanje vrednosti v indikatorjih obremenitve v "2D speckle-tracking" nastavitvi je najbolj nazorno predstavljeno s spremembami v segmentalni sistolični funkciji levega ventrikla v začetnem stadiju hipertrofične kardiomiopatije.

anterolateral segments of the left ventricular myocardium and a compensatory increase in the contralateral segments were revealed. This served as an indication to start treatment.

**Conclusion:** A decrease in strain indicators in the 2D speckle-tracking mode is most informatively represented by changes in segmental systolic function of the left ventricle at the initial stage of HCM.

## INTRODUCTION

Hypertrophic cardiomyopathy (HCM) is the most common, genetically determined myocardial disease in children (1). In recent years, the number of reported cases has increased due to improved diagnostic equipment, examination methods, and mass molecular genetic screening of family members (2). In children, the prevalence of HCM is 3–5:1,000,000. The annual mortality from this pathology according to different authors is 3–8% (3,4). Unfortunately, often the first and only manifestation of the disease is the sudden death of a child (5).

To detect myocardial hypertrophy, the most accessible and informative method of examination is echocardiography (6). Carrying out a routine echocardiography examination in children with HCM allows to assess the changes in global pumping and contractile function of the left ventricle using parameters such as ejection fraction (EF) and shortening fraction (FS) (7). Initially, dysfunction occurs in individual segments of the left myocardial ventricle. Only when the majority of myocardial segments are involved in the pathological process is a decrease in EF and FS diagnosed (8). These indicators in children with HCM remain within the normal range for a long time due to the compensatory mechanisms of the myocardium. This creates an effect of perceived well-being and, as a result, delays treatment (9).

The 2D speckle tracking mode in echocardiography is the most informative in assessment of local systolic function of the myocardium. This is a non-invasive method of ultrasound imaging of the heart, which allows to evaluate the kinetics of the myocardium. The method is based on the ultrasonic tracking of "spots" or speckle in the myocardial tissue, as a result of which a spectral

pattern is formed. Speckle is unique to every part of the myocardium. It reflects the movement of myocardial tissue. The operating system follows the speckle in the 2D plane, defining its movement path or tracking. The movement of these sections of the myocardium can be calculated by choosing certain parts of the image. Myocardial displacement or strain is the main parameter derived from this information. Using the 2D speckle-tracking mode for the echocardiography examination, myocardial strain in the longitudinal, radial, and circular directions can be determined. This method does not depend on the scanning angle and also allows to estimate local contractility off-line, which is especially important in children (10).

This case report describes an unusual case of segmental myocardial contractility changes in the early stages of the disease in a teenager with HCM using the 2D speckle-tracking mode in an echocardiography examination.

## CASE REPORT

A 14-year-old boy was admitted to the hospital complaining of rapid fatigue after physical exertion. The boy was professionally involved in sports for the course of one year. During intensive training (>5 h a week), he began to note rapid fatigue and deterioration of well-being. At a routine medical examination before a competition, an electrocardiogram (EKG) revealed left ventricular myocardial hypertrophy.

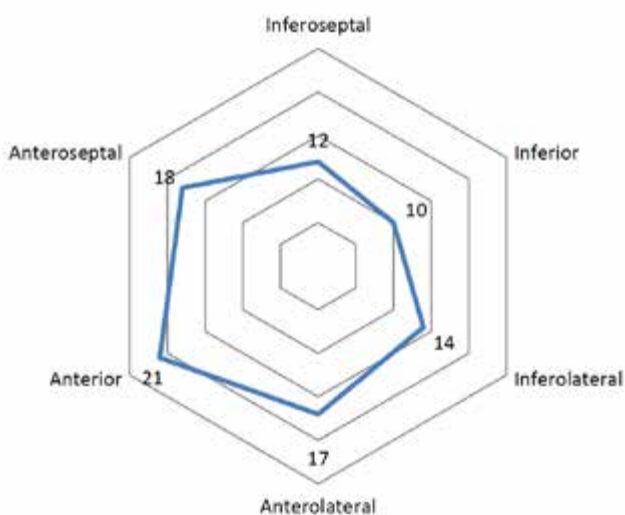
Upon admission to the hospital, the physical data were normal. The hereditary history included a sudden death of the paternal grandfather at the age of 35 years and

hypertension and myocardial hypertrophy in the father, which was revealed at the age of 36 years.

An EKG showed signs of left ventricular myocardial hypertrophy. On the EKG monitoring during the day, single supraventricular extrasystoles were observed, as well as a pause of rhythm due to sinus arrhythmia up to 1412 ms. During the stress test (treadmill test) throughout the study, rhythm disturbances were not recorded. A slight decrease in exercise tolerance was determined.

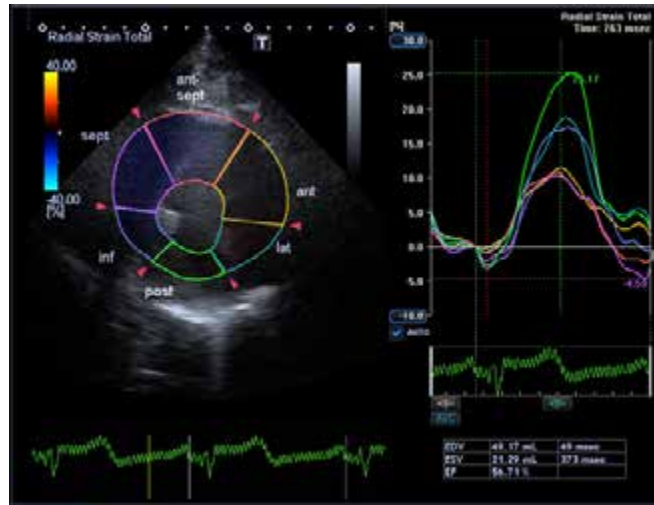Laboratory investigation, including haematological, biochemical, and hormonal tests, as well as urinalysis, were within normal range. Specific biochemical markers of myocardial ischemia (creatine kinase, lactate dehydrogenase, myoglobin, and troponins M, I) were also within relevant ranges.

Ultrasound examination of the heart was carried out on an Artida apparatus from Toshiba (Toshiba Medical Systems Corporation, Otawara City, Tochigi Prefecture, Japan) according to a standard method. The EF and FS of the left ventricle were determined using the Simpson's method. The EF was 57% and FS was 30%. Obstruction of the left ventricular exit tract was not revealed. The left ventricular myocardial mass index was 167 g/m<sup>2</sup> (MMLV). In mode B, the average values of the myocardial thickness were determined using 12 segments, with the exception of four apical segments (10). A diagram was constructed, where the mean myocardial thickness in each segment was expressed in millimeters (Fig. 1).



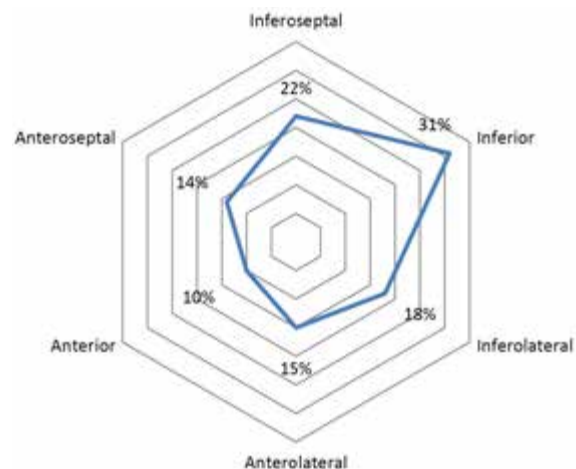
**Figure 1.** Thickness of the myocardium of the left ventricle on each segment (the 16th segment scheme of the left ventricle is used).

Myocardial thickness values were converted into units of standard deviation in the population (z-score factor), which amounted to 4.29Z (8). In the 2D speckle-tracking mode, the global and segmental longitudinal, circular, and radial myocardial strain was evaluated in 12 segments of the basal and middle parts of the left ventricle (Fig. 2).



**Figure 2.** Screenshot. Measurement of the left ventricular radial myocardium strain in 2D speckle-tracking mode. Parasternal position along the short axis of the left ventricle at the level of the papillary muscles of the mitral valve.

Analysis of the integral deformation curves revealed a decrease in the indices below the corresponding values (20%) (8) in the anteroseptal, anterior, and anterolateral segments. In addition, an increase in strain parameters in the contralateral segments



**Figure 3.** Mean values of parameters strain (Longitudinal, Circular, Radial) myocardium of the left ventricle.

was revealed. This testified to the pronounced compensatory mechanisms of the myocardium in this child (Fig. 3).

The boy underwent a genetic analysis for the presence of hereditary forms of cardiomyopathy. A mutation for cardiac myosin-binding protein C has been discovered, which can lead to HCM.

The following diagnosis was made: HCM, asymmetric form, without obstruction. It was decided to prescribe a comprehensive cardioprotective therapy (Atenolol 50 mg/day, L-carnitine 5 mL three times a day).

## DISCUSSION

This report presents a clinical case of a patient with HCM, which revealed changes in segmental systolic function of the left ventricular myocardium using the 2D speckle-tracking mode during echocardiography. Currently, the identification of the early signs of changes in local myocardial contractility is an urgent issue in this cohort – children with HCM of patients (9). Magnetic resonance imaging (MRI) of the heart is the "gold standard" for assessing local segmental myocardial contractility, which displays such an indicator as strain (6). With the development of ultrasound imaging

methods in recent years, the determination of myocardial strain indicators has also become available in the 2D speckle-tracking mode with echocardiographic examination (10). The advantages of 2D speckle tracking over MRI are the lower cost of the study, the absence of risk of side effects, and a wider range of applications for assessing local myocardial contractility in children with HCM (10,11). Assessment of segmental systolic function in the 2D speckle-tracking mode is widely used as a diagnostic criterion in the adult population (10). In children, this technique has a number of technical difficulties in connection with the physiological characteristics of the children's heart (10,11). However, as shown in the present report, changes in strain indicators in children with HCM are more sensitive and informative than other research parameters (EKG, biochemical markers of myocardial ischemia, and EF and FS of the left ventricle).

## CONCLUSIONS

The decrease in strain indicators in the 2D speckle-tracking mode is most informatively represented by changes in segmental systolic function of the left ventricle at the initial stage of HCM.

## REFERENCES

1. Moak JP, Kaski JP. Hypertrophic cardiomyopathy in children. *Heart* 2012; 98: 1044–54.
2. Elliott PM, Anastakis A, Borger MA, Borggrefe M, Cecchi F, Charon P et al. 2014 Guidelines on diagnosis and management of hypertrophic cardiomyopathy. The Task Force for the Diagnosis and Management of Hypertrophic Cardiomyopathy of the European Society of Cardiology (ESC). *Eur Heart J* 2014; 39: 2735–9.
3. Maron BJ, McKenna WJ, Danielson GK, Kappenberger LJ, Kuhn HJ, Seidman CE et al. American College of Cardiology/European Society of Cardiology clinical expert consensus document on hypertrophic cardiomyopathy. A report of the American College of Cardiology Foundation Task Force on Clinical Expert Consensus Documents and the European Society of Cardiology Committee for Practice Guidelines. *J Am Coll Cardiol* 2003; 9: 1687–713.
4. Maron BJ. Prevention of sudden death with the implantable defibrillator in hypertrophic cardiomyopathy. *Rev Esp Cardiol* 2006; 59: 527–30.
5. Ly HQ, Greiss I, Talakic M, Guerra PG, Macle L, Thibault B et al. Sudden death and hypertrophic cardiomyopathy: a review. *Can J Cardiol* 2005; 5: 441–8.
6. Lang RM, Badano LP, Mor-Avi V, Afilalo J, Armstrong A, Ernande L et al. Recommendations for cardiac chamber quantification by echocardiography in adults: an update from the American Society of Echocardiography and the European Association of Cardiovascular Imaging. *J Am Soc Echocardiogr*

- diogr 2015; 28:1–39.
7. Williams LK, Frenneaux MP, Steeds RP. Echocardiography in hypertrophic cardiomyopathy: diagnosis, prognosis and role in management. *Eur J Echocardiogr* 2009; 10: 9–14.
  8. Chernykh NYu, Groznova OS, Dovgan MI, Podolsky VA. A change in myocardial deformity as an early marker for myocardial dysfunction in children with hypertrophic cardiomyopathy. *RosVestn Perinatol I Pediatr* 2016; 5: 70–4.
  9. Losi MA, Nistri S, Galderisi M, Betocchi S, Cecchi F, Olivotto I et al. Echocardiography in patients with hypertrophic cardiomyopathy: usefulness of old and new techniques in the diagnosis and pathophysiological assessment. *Cardiovasc Ultrasound* 2010; 8: 7.
  10. Voigt JU, Pedrizzetti G, Lysyansky P, Marwick TH, Houle H, Baumann R et al. Definitions for a common standard for 2D speckle tracking echocardiography: consensus document of the EACVI/ASE/Industry Task Force to standardize deformation imaging. *Eur Heart J Cardiovasc Imaging* 2015;16:1–11.
  11. Yu AF, Raikhelkar J, Zabor EC, Tonorezos ES, Moskowitz CS, Adsuar R et al. Two-dimensional speckle tracking echocardiography detects subclinical left ventricular systolic dysfunction among adult survivors of childhood, adolescent, young adult cancer. *Biomed Res Int* 2016; 2016: e9363951.