

# Kirurško zdravljenje travmatske spondilolisteze

## 2. vratnega vretenca

### Surgical management of traumatic spondylolisthesis of the axis

#### Avtor / Author

Ustanova / Institute

Igor Movrin<sup>1,2</sup>, Andrej Čretnik<sup>1,2</sup>

<sup>1</sup>Univerzitetni klinični center Maribor, Oddelek za travmatologijo, Maribor, Slovenija;

<sup>2</sup>Univerza v Mariboru, Medicinska fakulteta, Maribor, Slovenija

<sup>1</sup>University Medical Centre Maribor, Department of Traumatology, Maribor, Slovenia;

<sup>2</sup>University of Maribor, Faculty of Medicine, Maribor, Slovenia

#### Ključne besede:

2. vratno vretenca (okretač), travmatska spondilolisteza, hangman zlom (zlom obešenca), sprednja zatrditev vratne hrbtenice

#### Key words:

axis, traumatic spondylolisthesis, Hangman's fracture, anterior cervical spine fusion

#### Članek prispel / Received

17.12.2012

#### Članek sprejet / Accepted

01.07.2013

#### Naslov za dopisovanje /

#### Correspondence

Asist. dr. Igor Movrin, dr. med., spec. travmatolog, Univerzitetni klinični center Maribor, Oddelek za travmatologijo, Ljubljanska 5, 2000 Maribor, Slovenija

Telefon +386 23211348

+386 41346869

E-pošta: igor.movrin@triera.net

#### Izvleček

**Namen:** Izbira načina zdravljenja travmatskih spondilolistez drugega vratnega vretenca (TSA) je še vedno polemično vprašanje. Za zdravljenje teh poškodb so bile uporabljene številne neoperativne in operativne metode.

**Poročilo o primeru:** Opisan je primer 29-letne ženske, ki je obiskala urgenco po padcu na stopnicah. Tožila je predvsem o hudih bolečinah v vratu. Na nativnih RTG posnetkih in slikah računalniške tomografije (CT) je bil viden obojestranski zlom pediklov drugega vratnega vretenca z večjim premikom telesa drugega vratnega vretenca naprej. V položaju z nekoliko podložnim vratom (hiperekstenzija) ji je bila nastavljena Crutchfield skeletna trakcija s pomočjo štirih kg. Po dveh urah skeletne trakcije je rentgenogram pokazal skoraj anatomski položaj. Še isti dan je bila pri pacientki s sprednjim pristopom opravljena odstranitev med-

#### Abstract

**Purpose:** The optimal treatment modality for traumatic spondylolisthesis (TSA) of the axis (second cervical vertebra) remains controversial. Many conservative and anterior techniques have been used to treat these injuries.

**Case report:** We describe a 29-year-old woman who presented to the emergency department with severe neck pain after falling down a flight of stairs. Cervical plain radiographs and computer tomography (CT) scan demonstrated a major C2 body anterior dislocation with bilateral C2 pedicle fractures. A Crutchfield extension was applied, with four kilograms of traction initially, with the neck in slight extension. After two hours of traction, plain radiographs showed near-anatomical reduction. The same day the patient underwent an anterior C2/C3 dis-

vretenčne ploščice C2/C3 in opravljena zatrditev z avtolognim kostnim transplantatom in kotno stabilno ploščico za vratno hrbtenico. V pooperativnem obdobju pri pacientki, ki je bila brez bolečin v vratu oz. drugih težav, nevroloških izpadov nismo ugotavljali. Rana je celila brez zapletov in pacientka je bila odpuščena domov 8. pooperativni dan z nameščeno Philadelphia ovratnico za obdobje 6-ih tednov.

**Zaključek:** Glede na naše izkušnje je v primeru nestabilnih TSA odstranitev medvretenčne ploščice C2/C3 in sprednja zatrditev tega segmenta možen in varen poseg. V rokah izkušenega kirurga je možna anatomska repozicija, dobra primarna stabilnost, visoka stopnja zatrditve in želeni klinični rezultati.

cectomy and autologous bone fusion with a cervical spine locking plate (CSLP). There were no neurological deficits postoperatively and the patient was asymptomatic. She was discharged home on postoperative day eight with a Philadelphia collar for 6 weeks.

**Conclusion:** Anterior C2/C3 discectomy and fusion may be feasible and safe in unstable TSA, with the benefit of high primary stability, anatomical reduction, a high union rate, and favorable clinical outcome.

## INTRODUCTION

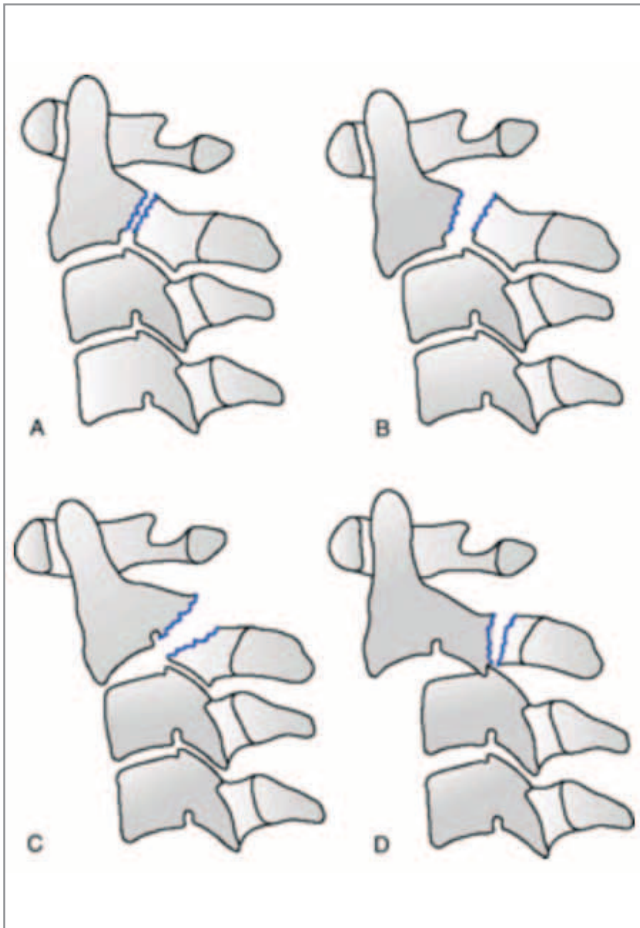
Traumatic spondylolisthesis of the axis (TSA) is a term used to describe bilateral fractures through the axial neural arch, which may result in anterior displacement of the second cervical vertebra on the third. This fracture was first described by Wood-Jones in 1913 in inmates who were executed by hanging, later coined "Hangman's fracture" (1). Today, this injury is most commonly caused by motor vehicle collisions or falls.

Among the different categories of TSA, the classification system proposed by Effendi and modified by Levine and Edwards (Figure 1) is most frequently used (2). Effendi et al. classified TSA based on its appearance, and putative mechanism, as follows: type I, isolated hairline fractures of the ring of the atlas with minimal displacement of the body of C-2 (axial loading end hyperextension); type II, displacement of the anterior fragment with disc disruption (hyperextension and rebound flexion); and type III, fixed displacement and angulation of the anterior segment with locked facets (3). Within the type II group, a subset of injuries was added by Levine and Edwards: those with minimal anterior translation but very severe angulation were designated as Type IIa (4).

TSA has therefore various stable and unstable types.

Type I lesions are usually considered stable with no angulation and displacement on C2/C3, whereas types II, IIa, and III are usually considered unstable. Unstable types all include injuries of the C2/C3 discs and anterior longitudinal ligament (4)

The optimal strategy to treat unstable TSA remains controversial. Conservative strategies that include traction and external immobilization for unstable TSA often have poor results during the follow-up period (5, 6). When significant displacement and instability exists, surgical reduction and stabilization is performed, usually by anterior fusion of C2 and C3 or by posterior fusion of the upper cervical vertebrae. When TSA is suspected in our institution, plain radiography and CT are routinely performed. The criteria of Roy-Camille et al. for instability are evaluated on lateral images (Figure 2) (7). These include the width of the fracture line, regional angulation (RA) in degrees, described as positive for kyphotic deformities and negative for lordotic deformities and anterior translation (AT) in millimeters. Surgery is indicated in patients with severe lesions of the mobile segment of C2/C3 with displacement more than 3 mm of AT, local kyphosis greater than 15°, or a lordosis of more than 5°.

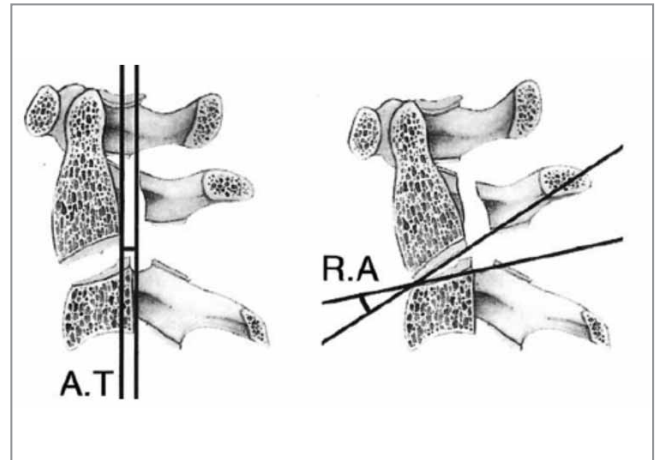


**Figure 1. Levine and Edwards classification**

**A – type I:** Minimally displaced with no angulation; translation <3 mm, stable. **B – type II:** Significant angulation at C2/C3; translation >3 mm; unstable; C2/C3 disc disrupted. **C – type IIIa:** Avulsion of entire C2/C3 intervertebral disc in flexion, leaving the anterior longitudinal ligament intact; results in severe angulation. No translation; unstable due to flexion–distraction injury. **D – type III:** Rare; results from initial anterior facet dislocation of C2 on C3 followed by extension injury fracturing the neural arch; results in severe angulation and translation with unilateral or bilateral facet dislocation of C2/C3; unstable.

## CASE PRESENTATION

A 29-year-old female presented to our emergency department with severe neck pain after falling down a flight of stairs. On physical examination, she had a forehead contusion but no neurological deficit. Cervi-



**Figure 2. The criteria of Roy–Camille et al for instability**

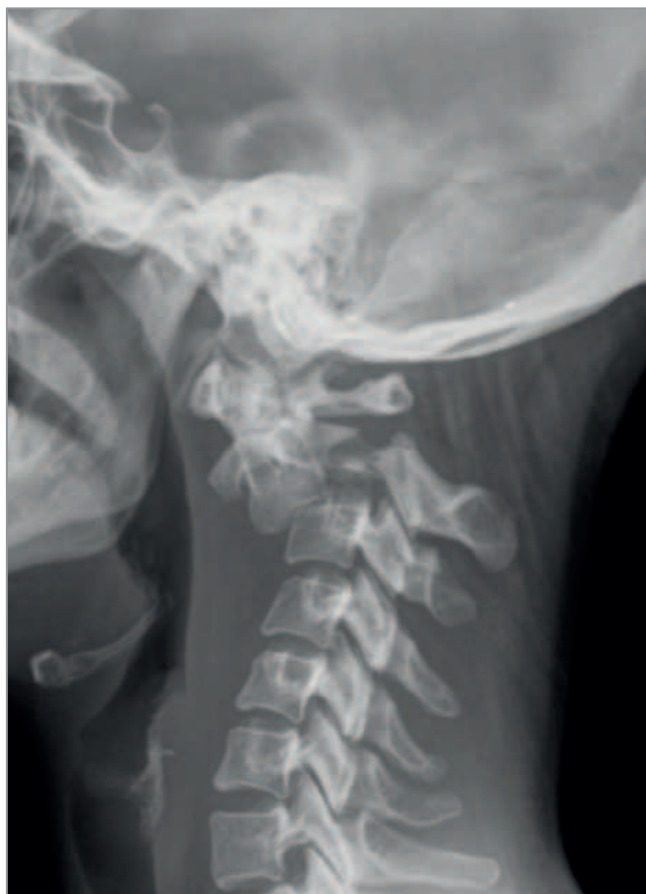*AT* – anterior translation, *RA* – regional angulation

cal plain radiographs and computerized tomography (CT) demonstrated a major C2 body anterior dislocation with bilateral C2 pedicle fractures (Figure 3), and was classified as a type II TSA of C2.

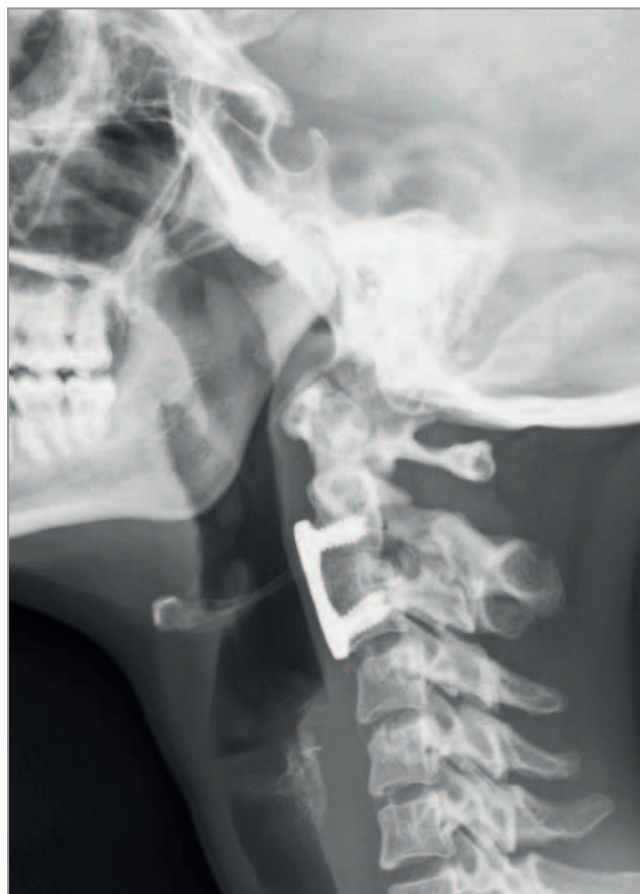A cranial halo was applied and four kilograms of traction was initially used, with the neck in slight extension. After two hours of traction, plain radiographs demonstrated near-anatomical reduction. The same day, the patient underwent surgery.

While in the supine position, an incision was made, midway between the angle of the jaw and the thyroid cartilage. Anterior exposure of C2 and C3 was obtained. After C2/C3 discectomy, autologous tricortical iliac crest bone was taken to graft the intervertebral space. An appropriate cervical spine locking plate (CSLP) was selected to allow sufficient adaptation on the C2 and C3 vertebral bodies, and final alignment was achieved by tightening the screws. The wound was closed over a drain, which was removed on postoperative day two. The patient was discharged home on postoperative day eight with a Philadelphia collar for 6 weeks.

To date, we have followed the patient for approximately 6 months postoperatively. On periodic examination and radiological follow up, sound bone fusion has been demonstrated (Figure 4) and the patient remains asymptomatic without neurologic deficit.



**Figure 3.** Lateral x-ray image showing a type II TSA with severe angulation and translation.



**Figure 4.** Lateral x-ray image 6 month postoperatively showing sound bone C2/C3 fusion

## DISCUSSION

In TSA, the indications for operative versus conservative management remains controversial. Some authors argue for surgical intervention only in type III TSA, or for chronic instability after non-surgical treatment (8). In addition, healing in a malunion position with anterior displacement is common without surgery and may be not harmful (2). Indeed, accurate fracture reduction and realignment of C2 and C3 is seldom achieved in conservative management of unstable TSA (9).

Pseudoarthrosis, and anterior dislocation or angulation of C2 over C3 and recurrent axial pain has been observed in approximately 60% of type II, type IIa, and type III TSA injuries that were primarily treated with nonoperative treatment (4-6). This fact may explain why many authors choose surgery in unstable TSA (10-12). The proportion of surgical cases varies

widely from one series to the next; most publications fail to provide a detailed description of the radiological criteria used to define the type of fracture and the degree of instability. Despite developments in diagnostic and surgical techniques, the optimal surgical treatment remains indeterminate.

Treatment decisions in our institution are based on stability of the existing fracture. Stability of the disc and discoligamentous integrity should be discussed. These pathomorphologic findings must be assessed prior to treatment of TSA using dynamic x-rays, MRI, or at least by observation of the clinical and radiologic course as an inpatient while in the Philadelphia collar. When criteria for instability are met, indicating the need for surgery, an anterior approach using a C2/C3 graft and plate fusion is usually preferred. There are specific indications for a posterior approach, as in cases with encroachment of the C2/

C3 neuroforamen due to facet fragments, non-reducible dislocations of C2/C3, contraindications to the anterior approach, among other reasons.

## CONCLUSION

In conclusion, we have described a case of unstable TSA treated with anterior C2/C3 discectomy, and graft and plate fusion, although this is not the commonly accepted primary method of managing this injury.

We do not recommend Halo fixation for extended periods or tong traction in the treatment of unstable TSA, given the availability of current surgical techniques. We concur, as previously described, that the anterior approach with primary internal stabilization may be feasible and safe in the treatment of unstable TSA (13). Lastly, we assert that if anterior fusion is used to treat a fracture-dislocation at the C3/C4 level today, it is difficult to argue against using the same principle for C2/C3 injuries.

## REFERENCES

1. Rayes M, Mittal M, Rengachary SS, Mittal S. Hangman's fracture: a historical and biomechanical perspective. *J Neurosurg Spine*. 2011 Feb; 14(2): 198–208.
2. Li X-F, Dai L-Y, Lu H, Chen X-D. A systematic review of the management of hangman's fractures. *Eur Spine J*. 2006 Feb 28; 15(3): 257–69.
3. Effendi B, Roy D, Cornish B, Dussault RG, Laurin CA. Fractures of the ring of the axis. A classification based on the analysis of 131 cases. *J Bone Joint Surg Br*. 1981; 63-B(3): 319–27.
4. Levine AM, Edwards CC. The management of traumatic spondylolisthesis of the axis. *J Bone Joint Surg Am*. 1985 Jan 31; 67(2): 217–26.
5. Coric DD, Wilson JAJ, Kelly DLD. Treatment of traumatic spondylolisthesis of the axis with non-rigid immobilization: a review of 64 cases. *J Neurosurg*. 1996 Sep 30; 85(4): 550–4.
6. Vaccaro ARA, Madigan LL, Bauerle WBW, Blescia AA, Cotler JMJ. Early halo immobilization of displaced traumatic spondylolisthesis of the axis. *CORD Conference Proceedings*. 2002 Oct 14; 27(20): 2229–33.
7. Roy-Camille R, Bleyne JF, Saillant G, Judet T. [Odontoid process fractures associated with fractures of the pedicles of the axis (author's transl)]. *Rev Chir Orthop Reparatrice Appar Mot*. 1979 Oct; 65(7): 387–91.
8. Francis WRW, Fielding JWJ, Hawkins RJR, Pepin JJ, Hensinger RR. Traumatic spondylolisthesis of the axis. *J Bone Joint Surg Br*. 1980 Dec 31; 63-B(3): 313–8.
9. KOLLER H, DANIAUX H, GRUBER H, Blauth M, KATHREIN A. Die instabile traumatische spondylolisthese C2/3 – Ergebnisse und Empfehlungen nach operativer Stabilisierung in 34 Fällen und Literaturübersicht. *Aktuelle Traumatologie*. Thieme; 2005; 35(4): 183–202.
10. Taller SS, Suchomel PP, Lukás RR, Beran JJ. CT-guided internal fixation of a hangman's fracture. *Eur Spine J*. 2000 Sep 30; 9(5): 393–7.
11. Verheggen R, Jansen J. Hangman's Fracture: Arguments in Favor of Surgical Therapy for Type II and III according to Edwards and Levine. *Surgical Neurology*. 1998 Mar; 49(3): 253–62.
12. Samaha CC, Lazennec JYJ, Laporte CC, Saillant GG. Hangman's fracture: the relationship between asymmetry and instability. *J Bone Joint Surg Br*. 2000 Aug 31; 82(7): 1046–52.
13. Xu H, Zhao J, Yuan J, Wang C. Anterior discectomy and fusion with internal fixation for unstable hangman's fracture. *Int Orthop*. 2010 Feb; 34(1): 85–8.