

Kirurško zdravljenje akutnega izpaha pogačice s kostnim odlomkom pri otrocih

Surgical treatment of acute patellar dislocation associated with bony avulsion in children

Avtor / Author

Ustanova / Institute

Samo K. Fokter^{1,2}, Andraž Dovnik^{1,2}, Nina Fokter Dovnik^{1,2}

¹Univerzitetni klinični center Maribor, Klinika za kirurgijo, Oddelek za ortopedijo, Maribor, Slovenija; ²Univerza v Mariboru, Medicinska fakulteta, Katedra za medicino in šport, Maribor, Slovenija

¹University Clinical Centre Maribor, Division of Surgery, Department of Orthopaedics, Maribor, Slovenia; ²University of Maribor, Faculty of Medicine, Department of medicine and sports, Maribor, Slovenia

Ključne besede:

akutni izpah pogačice, patelofemoralna kostna avulzija, izpah pri otrocih, pediatrične poškodbe, kirurško zdravljenje.

Key words:

acute patellar dislocation, patellofemoral bony avulsion, dislocation in children, pediatric injury, surgical treatment

Članek prispel / Received

22.07.2012

Članek sprejet / Accepted

05.05.2013

Naslov za dopisovanje / Correspondence

Doc. dr. Samo K. Fokter
Klinika za kirurgijo, Oddelek za ortopedijo, Univerzitetni klinični center Maribor, Ljubljanska 5, SI-2000 Maribor, Slovenija
Telefon +386 23211541

Izvleček

Namen: O zdravljenju akutnega izpaha pogačice pri otrocih in mladostnikih še ni jasnega konsenza. Tradicionalno zdravljenje prvega poškodbenega izpaha pogačice je bilo konzervativno, zaradi novih spoznanj o medialnih stabilizatorjih pogačice pa nekateri avtorji v zadnjem času priporočajo operacijsko zdravljenje. Pričujoča raziskava opisuje srednjeročne subjektivne in funkcionalne rezultate operacijskega zdravljenja akutnega izpaha pogačice s pridruženim osteohondralnim odlomkom pri otrocih in mladostnikih, mlajših od osemnajst let.

Metode: Retrospektivno smo zbrali podatke 16 bolnikov (osmih deklic in osmih dečkov), povprečno starih 14,9 (12–17) let z akutnim izpahom pogačice. Pri vseh bolnikih smo na rentgenskih posnetkih ugotovili prisotnost

Abstract

Purpose: The management of acute patellar dislocation in children and adolescents is controversial. Traditionally, most first-time traumatic patellar dislocations have been treated nonoperatively. However, due to new knowledge about medial patellar stabilizers some authors have advocated for surgical repair. The present report describes the mid-term subjective and functional results of operative treatment of acute patellar dislocation in children less than eighteen years of age with concomitant osteochondral fracture.

Methods: Data on a cohort of sixteen patients (eight girls and eight boys) aged 14.9 years (mean, range 12–17 years) with acute patellar dislocation were retrospectively collected. Intraarticular fragments were

znotraj sklepnih odlomkov. Bolnike smo operacijsko zdraveli z artroskopsko odstranitvijo (12 primerov) ali refiksacijo (4 primeri) osteohondralnih odlomkov in neposrednim popravlilom medialne patelofemoralne vezi, kjer je bilo to še mogoče (13 primerov). Bolnike smo pregledali po šestih mesecih in z dvanajstimi (75 %) opravili telefonski pogovor po povprečno štirih (2–7) letih.

Rezultati: Dva izmed 16 bolnikov (12,5 %) sta imela ponovni izpah pogačice. Povprečno doseženo število točk po subjektivnem IKDC točkovniku ob zadnjem sledenju je bilo 86 (63–100), po Marx Activity Rating Scale pa 9,2 (2–16).

Zaključki: Neposredna kirurška rekonstrukcija medialne patelofemoralne vezi predstavlja možnost preprečitve ponovne dislokacije in subluksacije pogačice. Posebej primerna je lahko ob prvem travmatskem izpahu pogačice pri otrocih in mladostnikih z osteohondralnimi zlomi in obsežnejšo okvaro medialnih stabilizatorjev pogačice.

detected in all patients in conventional radiographs. Operative treatment consisted of arthroscopic removal (12 cases) or refixation (4 cases) of the osteochondral fragments and direct repair of the damaged medial patellofemoral ligament (MPFL) if that was still feasible (13 cases). All patients were seen at six months, and a telephone interview with twelve patients (75%) was conducted at four years (mean, range 2–7 years).

Results: Of the sixteen patients, two (12.5%) had a recurrent patellar luxation. The subjective IKDC score at the time of the most recent follow-up was 86 (mean, range 63–100), and the Marx Activity Rating Scale score was 9.2 (mean, range 2–16).

Conclusions: Direct surgical repair of the injured MPFL may be considered an option to prevent subsequent dislocation and subluxation in first-time traumatic dislocation of the patella in children and adolescents with osteochondral fractures and substantial disruption of medial patellar stabilizers.

INTRODUCTION

Acute patellar dislocation represents 2–3% of all knee injuries (1). In children and teenagers, it is the most frequent acute trauma of the knee (2). Its etiologic factors include anatomic abnormalities, female gender, age between 10 and 17 years, positive family history, and body height and weight (3, 4). Since the patella dislocates laterally, this injury affects the medial patellar stabilizers. While the medial joint capsule is torn directly off the patella in the majority of cases, other authors report a parapatellar rupture of the medial capsule (5, 6). Bassett reported that the most vulnerable point in this group of patients is located above the adductor tubercle of the femur (7). In 1996, the discussion of the anatomy of patellar dislocation changed, when Sallay et al. demonstrated a tear of the femoral insertion of the medial patellofemoral ligament (MPFL), with an enhanced signal and retraction of the distal muscular part of the vastus medialis obliquus (VMO) muscle on magnetic resonance imaging (MRI) (8).

Knowledge of the anatomy of the medial knee is essential for appropriate diagnosis and treatment of acute patellar dislocation (9, 10). Functional studies of medial soft-tissue restraints in the prevention of lateral patellar displacement were performed using biomechanical testing (11). The MPFL, although varying in size and importance, was found to be the major medial soft-tissue restraint that prevented lateral displacement of the distal knee-extensor mechanism, contributing an average of 53% of the total force. The medial patellomeniscal ligament (MPML) and associated retinacular fibers in the deep capsular layer of the knee – previously thought to be functionally unimportant in patellar stabilization – contributed 22% of the total force; while the medial patellar retinaculum (MPR) only contributed 11%. These results were confirmed by Desio et al., who left the lateral patellar retinaculum (LPR) intact, allowing free rotation of the patella (12). These authors concluded that the MPFL con-

tributes 60%, the MPML 13%, and the LPR 10% of the total force of restraint to lateral patellar translation at 20° flexion. In other words, the MPFL passively prevents incomplete patellar dislocation and is the primary structure damaged in acute patellar dislocation. The VMO muscle is the primary medial dynamic stabilizer and can also be injured in acute patellar dislocation.

Nonoperative treatment of acute patellar dislocation often leads to recurrent dislocations or patellar instability (13). It was reported that 44% of redislocations occur after closed reposition and immobilization for an average of 3.5 weeks (14). Twenty years later, in a larger series of patients with a 13-year mean follow-up, the same redislocation rate remained (44%), with an additional 19% of patients with patellofemoral pain or incomplete dislocations after the first episode; thus, conservative treatment was inefficient in 63% of patients (15). These findings resulted in an increasing number of reports on primary surgical treatment of first-time patellar dislocation with MPFL and VMO reconstruction (16–19; 20). Recently, surgery is becoming a viable option in the treatment of first-time patellar dislocations (21).

In this study, we present our results of surgical treatment of first-time patellar dislocation with associated osteochondral fractures in pediatric patients (22, 23).

MATERIAL AND METHODS

16 patients (8 female, 8 male; average age 14.9 years, range 12–17) with primary patellar dislocation sustained during physical activity were treated in the orthopaedic department of a district general hospital between 2002 and 2007. On palpation, the location of the most severe pain in all patients was above the adductor tubercle. All patients were initially treated by general surgeons, and were referred after spontaneous or closed reposition of the patella due to an osteochondral fracture found on plain radiographs with or without additional Merchant views (n=13; Figure 1). 3 patients did not improve with rehabilitation, or an intraarticular fracture was discovered later. The latter were referred several weeks after injury, and were therefore considered to have a delay in treatment. On average, surgical treatment was performed 44 days after dislocation (range 3–256 days).

Initially, arthroscopic knee examination and hematoma evacuation was performed in all patients. The position of the osteochondral fracture on the patellar groove or lateral femoral trochlea, and the free fragment (*corpus liberum*) were identified. In 12 patients, smaller fragments were arthroscopically removed. When a larger defect was found, the fragment was reinserted with screws (n=2) or resorbable pins (n=2) in an open procedure. A 5 cm oblique



Figure 1. Axial Merchant radiographic view after first-time patellar dislocation. The left side has been dislocated and the patella is lateralized. The right side is normal.

incision was made above the adductor tubercle, through which the distal part of the VMO was retracted, exposing the MPFL. In 13 cases, a rupture was found in the substance of the MPFL near the femoral insertion. In this situation, direct repair with a non-absorbable suture was used. In all patients, the VMO insertion on the tendon of the adductor magnus muscle was reconstructed. In the three patients whose treatment course was delayed, the MPFL could not be identified; open plication of the medial capsule and additional stabilization of the patellofemoral joint using the Fulkerson technique (oblique osteotomy and anteromedialization of the tibial tubercle; 24) was performed. The same stabilization procedure was performed in 4 cases where the patella remained unstable despite MPFL reconstruction. The decision for additional realignment was undertaken because of the surgeon's judgment of patellar instability, rather than considering a specific type of patellofemoral joint abnormality. In addition, the lateral patellar retinaculum was released in 6 cases due to shortened lateral structures preventing complete patellar centralization.

All patients participated in an accelerated rehabilitation program emphasizing immediate postoperative improvement of mobility. No brace was prescribed. When anteromedialization of the tibial tubercle was performed, weightbearing was restricted to 50% of the patient's body weight for the first six postoperative weeks. In the remaining patients, weight-bearing was limited as the pain allowed. Closed kinetic chain knee rehabilitation exercises for strength training were performed.

All patients were clinically observed for six months. Treatment was terminated at six months in patients who regained full mobility of the knee, adequate muscular strength, and complete radiological healing in cases of anteromedialization of the tibial tubercle. Results were evaluated using the subjective portion of the 100-point IKDC score (25, 26). Patient activity was assessed using the simple Marx 16-point activity rating scale (27). The latter evaluates four knee burdening activities (running, changing direction while running, rapid deceleration while running, and rotating the body with the foot fixed).

Each activity was scored between 0 to 4 points, according to frequency (0 – less than once a month, 1 – once a month, 2 – once a week, 3 – two/three times a week, 4 – four or more times a week).

RESULTS

There were no intraoperative or early postoperative complications. The internally fixed osteochondral fragments showed signs of bone healing in plain radiographs at three months. This was arthroscopically confirmed in 2 patients, in whom screws were removed three months postoperatively. The osteotomies due to tibial tubercle anteromedialization also completely healed three months postoperatively. All patients regained full range of motion of the knee and appropriate thigh strength, as determined by an experienced physiotherapist. 2 of 16 patients (12.5%) experienced a single recurrent patellar dislocation, six months and one year after the procedure, respectively, during strenuous sporting activities. They were both treated conservatively, because the patients and their families refused additional surgery.

At the final postoperative follow-up evaluation by phone (mean 3.75 years, range 2–7 years), the mean subjective IKDC score in 12 of 16 patients contacted was 86 out of 100 points (range 63–100). The mean knee function before the injury was estimated at 9.91 points on a scale of 1 to 10 (range 9 to 10), while mean knee function at follow-up was 8.17 (range 4–10). The mean drop of subjectively evaluated knee function was 1.74 points (17.4%; Figure 2). The mean Marx activity score was 9.2 (range 2–16) points.

DISCUSSION

Unsuccessful conservative treatment has influenced the early descriptions of surgical repair of acute patellar dislocation (28). Arthroscopic techniques have evolved from simple irrigation and debridement to release of the lateral retinaculum (29). However, these approaches did not improve results, even with open lateral capsulotomy after medial capsulorraphy (30). Lateral release in combination with

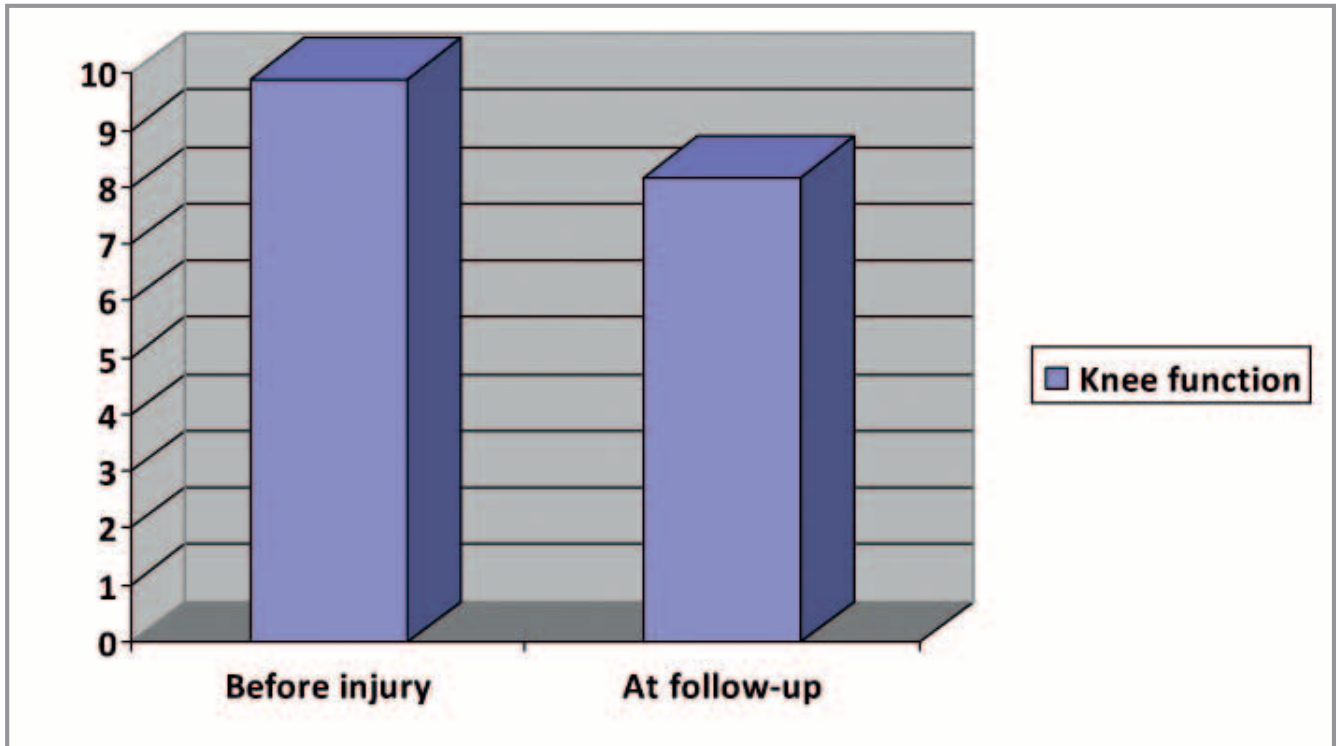


Figure 2. Mean subjective IKDC score of knee function before first-time patellar dislocation and at follow-up.

arthroscopic medial plication, an attractive method with low morbidity, did not allow for reconstruction of the damaged static and dynamic patellar stabilizers (31). Encouraging results with tenodesis of the MPFL with the distal portion of the adductor magnus muscle were reported by Avikainen et al.; however, this technique changes the insertion of the VMO and may compromise its function (32).

Analysis of the results of early surgical treatment of acute patellar dislocation was published by Sallay et al. (8). Standard X-rays and MRI were performed preoperatively in all patients, proving rupture of the femoral insertion of the MPFL in 87%, and an elevated signal from the vastus medialis muscle in

78%. Intraarticular lesions were evaluated and treated arthroscopically, followed by open exploration of the medial aspect of the knee. Exploration revealed tears of the MPFL off the femur in 94% of cases. After MPFL repair, none of the patients experienced recurrent dislocation. The authors established that MPFL repair results in a normal VMO orientation with the restoration of its normal insertion to the adductor tubercle of the femur. In a review of 8 cases of acute patellar dislocation, Ahmad et al. found tears of the MPFL off the adductor tubercle, and tears of the VMO off the adductor magnus tendon in all patients (16). The torn VMO muscle was retracted in an anterior and superior direction. The authors performed an arthroscopic lateral release followed by open primary repair of the MPFL to the adductor tubercle, and repair of the VMO muscle to the adductor magnus tendon, thus achieving its normal distal posterior position and the correct angle of fibers securing medial stabilization of the patella.

Sillanpää et al. performed a prospective study in which 40 young adults with acute patellar disloca-

ABBREVIATIONS

IKDC: international knee documentation committee

LPR: lateral patellar retinaculum

MCL: medial collateral ligament

MPFL: medial patellofemoral ligament

MPML: medial patellomeniscal ligament

MPR: medial patellar retinaculum

VMO: vastus medialis obliquus

tion were randomly assigned to either surgical stabilization or conservative treatment (33). After a median follow-up of seven years, they found a significantly lower redislocation rate in surgically treated patients, although this group showed no clear advantages in terms of subjective improvement, physical activity or anatomical healing.

In recent years, several studies tried to evaluate the role of MPFL repair for acute or recurrent patellar dislocation. Camp et al. found that isolated MPFL repair resulted in 72% prevention of recurrent patellar dislocations and emphasized the role of anatomical restoration of the MPFL origin and careful patient selection (34). A new method of MPFL reconstruction was proposed by Deie et al. (35), using a cylindrical bone plug and a grafted semitendinosus tendon at the femoral attachment site. Only 1 of the 31 treated patients showed signs of instability after an average follow-up of 3.2 years. Panni et al. evaluated MPFL reconstruction with the semitendinosus tendon using a divergent patellar transverse 2-tunnel technique (36). The overall satisfaction rate with pain relief was 87%. All 48 patients had played sports before surgery; only 20% reduced or changed their sports activity because of surgery. The authors reported no postoperative patellar dislocation during an average follow-up period of 33 months. However, in a study describing a similar transverse 2-tunnel technique using the hamstring tendon, Ronga et al. described 3 redislocations in 28 patients after 3.1 years of follow-up (37). Zhao et al. compared MPFL reconstruction to medial retinaculum plication in a randomized controlled trial (38). In a series of 100 patients, reconstruction of the MPFL resulted in better static and functional outcome. Although these studies show certain advantages to MPFL reconstruction, it is important to bear in mind the difficulty of reproducible MPFL reconstruction. This has been confirmed by Servien et al. who assessed postoperative femoral graft positioning (39). They evaluated 29 femoral tunnels using X-rays and MRI and found that less than 70% were in a proper location.

In our patients who were treated surgically soon after injury, we found injuries of the medial patel-

lar stabilizers similar to those described above. In some patients, the MPFL structure was tender and stretched. In those treated several weeks after injury, the structure was no longer anatomically discernible. Additional procedures for patellar stabilization were performed in these patients. Other authors used transplantation to strengthen the MPFL, thus avoiding extensive procedures on the knee extensors in an immature skeleton, which might be a drawback to our treatment (19, 40, 41).

Our study also has several limitations. First, imaging of the patellofemoral joint after dislocation was inadequate. MRI is recommended in cases of primary dislocation to precisely verify cartilage, reliably assess the location of the MPFL injury, and describe the anatomic structure of the patellofemoral joint (21). If we had performed an MRI soon after the injury, we would not have missed osteochondral fractures, the patients would have been treated earlier, and possible mid-substance tears of the MPFL would have been recognized. Secondly, in addition to the small number of patients and the retrospective scheme, we did not have a control group; our results could only be compared with published data. Prospective randomized studies in the pediatric population are scarce (42). A recently published analysis by Palmu et al. established a high percentage of recurrent dislocations in operatively (67%) and non-operatively (71%) treated children and teenagers after acute patellar dislocation (43). Nevertheless, the authors reported good or excellent long-term results in both groups of patients (66% and 75%, respectively). However, they did not advise operative treatment of patellar dislocation in children, arguing that in $\frac{1}{4}$ of surgically treated patients, only a release of the lateral retinaculum was performed (except in 4 cases), while treatment of medial stabilizer injuries varied. According to biomechanical and clinical studies, release of the lateral retinaculum is recommended solely when it helps to centralize the patella during the performance of other procedures (44). In contrast, Camanho et al. found in a randomized controlled trial of conservative versus surgical treatment for MPFL repair in acute dislocations of the patella, that recurrent dislocations were

more frequent when conservatively treated (8 of 16 vs. 0 of 17, respectively) (45).

Our results confirm the findings of Stefanicin and Parker, who performed a systematic analysis of 70 studies of first-time traumatic patellar dislocation in order to determine when to use operative versus conservative treatment (1). The authors recommended initial nonoperative treatment except in the presence of an osteochondral fracture, substantial disruption of the medial patellar stabilizers, a laterally subluxated patella with normal alignment of the contralateral knee, a second dislocation, or in patients not improving with appropriate rehabilitation. Our study demonstrates, for the first time, that treatment of patellar dislocation with osteochondral

fractures with MPFL reinsertion and fragment fixation results in stability of the patellofemoral joint in greater than 85% of (pediatric) cases.

CONCLUSION

The MPFL is of key importance for medial patellar stability. In our series, patients with acute patellar dislocation usually had the MPFL torn off its insertion to the adductor tubercle. Direct surgical repair of the damaged MPFL after a first-time traumatic dislocation with an osteochondral fracture and substantial disruption of the medial patellar stabilizers in children and teenagers may prevent subsequent dislocations and patellar instability.

REFERENCES

1. Stefanicin JJ, Parker RD. First-time traumatic patellar dislocation: A systematic review. *Clin Orthop* 2007; 455: 93–101.
2. Beasley LS, Vidal AF. Traumatic patellar dislocation in children and adolescents: treatment update and literature review. *Curr Opin Pediatr* 2004; 15: 281–5.
3. Fithian DC, Paxton EW, Stone ML, Silva P, Davis DK, Elias DA, et al. Epidemiology and natural history of acute patellar dislocation. *Am J Sports Med* 2004; 32: 1114–21.
4. Sillanpää P, Mattila VM, Iivonen T, Visuri T, Pihlajamäki H. Incidence and risk factors of acute traumatic primary patellar dislocation. *Med Sci Sports Exerc* 2008; 40: 606–11.
5. O'Donoghue DH. Treatment of injuries to athletes. 3rd ed. Philadelphia: WB Saunders Co, 1976: 600–17.
6. Sargent JR, Taipner WA. Medial patellar retinacular repair for acute and recurrent dislocation of the patella: A preliminary report. *J Bone Joint Surg* 1971; 53-A: 386.
7. Bassett FH. Acute dislocation of the patella, osteochondral fractures, and injuries to the extensor mechanism of the knee. *Instr Course Lect* 1976; 25: 40–9.
8. Sallay PI, Poggi J, Speer KP, Garrett WE. Acute dislocation of the patella. A correlative pathoanatomic study. *Am J Sports Med* 1996; 24: 54–60.
9. Warren LF, Marshall JL. The supporting structures and layers on the medial side of the knee. An anatomical analysis. *J Bone Joint Surg* 1979; 61-A: 56–62.
10. Reider B, Marshall JL, Ring B. Patellar tracking. *Clin Orthop* 1981; 157: 143–8.
11. Conlan T, Garth WP, Lemons LE. Evaluation of the medial soft-tissue restraints of the extensor mechanism of the knee. *J Bone Joint Surg* 1993; 75-A: 682–93.
12. Desio SM, Burks RT, Bachus KN. Soft tissue restraints to lateral patellar translation in the human knee. *Am J Sports Med* 1998; 26: 59–65.
13. McManus F, Rang M, Heslin J. Acute dislocation of the patella in children. The natural history. *Clin Orthop* 1979; 139: 88–91.

14. Cofield RH, Bryan RS. Acute dislocation of the patella: results of conservative treatment. *J Trauma* 1977; 17: 526–31.
15. Mäenpää H, Lehto MUK. Patellar dislocation. The long-term results of non-operative management in 100 patients. *Am J Sports Med* 1997; 25: 213–7.
16. Ahmad CS, Shubin Stein BE, Matuz D, Henry JH. Immediate surgical repair of the medial patellar stabilizers for acute patellar dislocation. A review of eight cases. *Am J Sports Med* 2000; 28: 804–10.
17. Buchner M, Baudendistel B, Sabo D, Schmitt H. Acute traumatic primary patellar dislocation: long-term results comparing conservative and surgical treatment. *Clin J Sports Med* 2005; 15: 62–6.
18. Fukushima K, Horaguchi T, Okano T, Yoshimatsu T, Saito A, Ryu J. Patellar dislocation: Arthroscopic patellar stabilization with anchor sutures. *Arthroscopy* 2004; 7: 761–4.
19. Smirk C, Morris H. The anatomy and reconstruction of the medial patellofemoral ligament. *The Knee* 2003; 10: 221–7.
20. Cash JD, Hughston JC. Treatment of acute patellofemoral dislocation. *Am J Sports Med* 1988; 16: 244–9.
21. Sillanpää PJ, Mäenpää HM. First-time patellar dislocation: Surgery or conservative treatment? *Sports Med Arthrosc Rev* 2012; 20: 128–35.
22. Nomura E, Inoue M, Kurimura M. Chondral and osteochondral injuries associated with acute patellar dislocation. *Arthroscopy* 2003; 19: 717–21.
23. Toritsuka Y, Horibe S, Hirooka A, Mitsuoka T, Nakamura N. Medial marginal fracture of the patella following patellar dislocation. *The Knee* 2007; 14: 429–33.
24. Fulkerson J. Anteromedialization of the tibial tuberosity for patellofemoral malalignment. *Clin Orthop* 1983; 177: 176–81.
25. Irrgang JJ, Anderson AF, Boland AL, Harner CD, Kurosaka M, Neyret P, et al. Development and validation of the international knee documentation committee subjective knee form. *Am J Sports Med* 2001; 29: 600–13.
26. Anderson AF, Irrgang JJ, Kocher MS, Mann BJ, Harrast JJ. The international knee documentation committee subjective knee evaluation form normative data. *Am J Sports Med* 2006; 34: 128–35.
27. Marx RG, Stump TJ, Jones EC, Wickiewicz TL, Warren RF. Development and evaluation of an activity rating scale for disorders of the knee. *Am J Sports Med* 2001; 29: 213–8.
28. Boring TH, O'Donoghue DH. Acute patellar dislocation. Results of immediate surgical repair. *Clin Orthop* 1978; 136: 182–5.
29. Dainer RD, Barrack RL, Buckley SL, Alexander AH. Arthroscopic treatment of acute patellar dislocations. *Arthroscopy* 1988; 4: 267–71.
30. Jensen CM, Roosen JU. Acute traumatic dislocation of the patella. *J Trauma* 1985; 25: 160–2.
31. Small NC, Glogau AI, Berezin MA. Arthroscopically assisted proximal extensor mechanism realignment of the knee. *Arthroscopy* 1993; 9: 63–7.
32. Avikainen VJ, Nikku RK, Seppänen-Lehmonen TK. Adductor magnus tenodesis for patellar dislocation. Technique and preliminary results. *Clin Orthop* 1993; 297: 12–6.
33. Sillanpää PJ, Mattila VM, Mäenpää H, Kiuru M, Visuri T, Pihlajamäki H. Treatment with and without initial stabilizing surgery for primary traumatic patellar dislocation. A prospective randomized study. *J Bone Joint Surg Am* 2009; 91(2): 263–73.
34. Camp CL, Krych AJ, Dahm DL, Levy BA, Stuart MJ. Medial patellofemoral ligament repair for recurrent patellar dislocation. *Am J Sports Med* 2010; 38(11): 2248–54.
35. Deie M, Ochi M, Adachi N, Shibuya H, Nakamae A. Medial patellofemoral ligament reconstruction fixed with a cylindrical bone plug and a grafted semitendinosus tendon at the original femoral site for recurrent patellar dislocation. *Am J Sports Med* 2011; 39(1): 140–5.
36. Panni AS, Alam M, Cerciello S, Vasso M, Maffulli N. Medial patellofemoral ligament reconstruction with a divergent patellar transverse 2-tun-

- nel technique. *Am J Sports Med* 2011; 39(12): 2647–55.
37. Ronga M, Oliva F, Longo UG, Testa V, Capasso G, Maffulli N. Isolated medial patellofemoral ligament reconstruction for recurrent patellar dislocation. *Am J Sports Med* 2009; 37(9): 1735–42.
 38. Zhao J, Huangfu X, He Y. The role of medial retinaculum plication versus medial patellofemoral ligament reconstruction in combined procedures for recurrent patellar instability in adults. *Am J Sports Med* 2012; 40(6): 1355–64.
 39. Servien E, Fritsch B, Lustig S, Demey G, Debarge R, Lapra C, et al. In vivo positioning analysis of medial patellofemoral ligament reconstruction. *Am J Sports Med* 2011; 39(1): 134–9.
 40. Nomura E, Inoue M, Osada N. Augmented repair of avulsion-tear type medial patellofemoral ligament injury in acute patellar dislocation. *Knee Surg Sports Traumatol Arthrosc* 2005; 13: 346–51.
 41. Inoue M, Nomura E, Sugiura H, Kobayashi S. Histological findings of avulsion tear-type medial patellofemoral ligament injury in acute patellar dislocation. *J Clin Pathol* 2007; 60: 1068–9.
 42. Hinton RY, Sharma KM. Acute and recurrent patellar instability in the young athlete. *Orthop Clin N Am* 2003; 34: 385–96.
 43. Palmu S, Kallio PE, Donell ST, Helenius I, Niemosvaara Y. Acute patellar dislocation in children and adolescents: A randomized clinical trial. *J Bone Joint Surg Am* 2008; 90: 463–70.
 44. Arendt EA, Fithian DC, Cohen E. Current concepts of lateral patella dislocation. *Clin Sports Med* 2002; 21: 499–519.
 45. Camanho GL, Viegas Ade C, Bitar AC, Demange MK, Hernandez AJ. Conservative versus surgical treatment for repair of the medial patellofemoral ligament in acute dislocations of the patella. *Arthroscopy* 2009; 25: 620–5.