

Spremljanje pretoka v možganskih arterijah s TCD

TCD monitoring of cerebral blood flow

Avtor / Author

Ustanova / Institute

Erih Tetičkovič, Marija Menih, Jožef Magdič

Oddelek za nevrološke bolezni, Univerzitetni klinični center Maribor, Slovenija

Department of Neurology, University Clinical Center Maribor, Slovenia

Ključne besede:

Transkranična Dopplerjeva sonografija, endarterektomija karotidnih arterij, karotidna angioplastika z znotrajžilno opornico, anevrizmatska subarahnoidna krvavitev, premostitev koronarnih arterij, tromboliza.

Key words:

Transcranial Doppler ultrasonography, carotid endarterectomy, carotid angioplasty with stenting, ruptured aneurysms in subarachnoid hemorrhage, coronary artery bypass grafting, thrombolysis.

Članek prispel / Received

06.03.2009

Članek sprejet / Accepted

02.04.2009

Naslov za dopisovanje /

Correspondence

Prof. dr. Erih Tetičkovič,
Oddelek za nevrološke bolezni,
Univerzitetni klinični center
Maribor, Ljubljanska 5,
2000 Maribor, Slovenija
Telefon: +386 2 321 23 64
Fax: +386 2 331 23 93
E-pošta: erih.tet@ukc-mb.si

Izvleček

Spremljanje pretoka po možganskih arterijah s transkranično Dopplerjevo sonografijo omogoča zaznavanje sprememb v pretoku po srednji možganski arteriji v dejanskem času. Pomembno je pri trombendarterektomiji karotidnih arterij, karotidni angioplastiki z znotrajžilno opornico, kirurškem zdravljenju anevrizem možganskih arterij, premostitvenih operacijah koronarnih arterij in trombolizi ob zapori srednje možganske arterije. Z ugotavljanjem zadostnega pretoka v srednji možganski arteriji pri karotidni trombendarterektomiji pomaga pri odločitvi o operaciji z znotrajžilnim obvodom ali brez tega. Hitro zaznavanje hipo- in hiperperfuzije, vazospazma, mikroembolusov ali rekanalizacije v možganskih arterijah lahko zmanjša tveganje za pooperativne nevrološke zaplete, kot sta možganska kap in kognitivna disfunkcija.

Abstract

Transcranial Doppler monitoring of intracranial blood flow during carotid endarterectomy, carotid angioplasty with stenting, surgical management of intracranial aneurysms, coronary artery bypass grafting, and thrombolysis of middle cerebral artery (MCA) occlusions is important because it enables recording of the flow in the MCA in real time. An adequate blood flow through the MCA during carotid endarterectomy allows for selective use of an intraluminal shunt (or the decision to operate without it) and timely identification of cerebral hyperperfusion, vasospasm, hypoperfusion, and cerebral microembolisms as well as recanalization of the cerebral artery, thus minimizing postoperative neurologic complications such as stroke or cognitive dysfunction.

INTRODUCTION

Intraoperative Doppler imaging of the intracranial arteries was first described in 1979 by Nornes and colleagues (1). They used a pulse device with small probes from 6 to 10 MHz. Transcranial Doppler (TCD) has since become a very important non-invasive method for assessing cerebral middle cerebral artery (MCA) during surgery (2). The results from intracranial blood flow examinations of the MCA during percutaneous transluminal aortic valvuloplasty (PTAV) were first described by Karnik et al. in 1985. They defined the critical value of the mean flow velocity (MFV) as being 30 cm/sec, with a normal flow velocity being 62 ± 12 cm/sec (3). TCD reveals direct changes in cerebral hemodynamics and perfusion, even before secondary metabolic changes, thus providing immediate information during the operation on the possible risks or effectiveness of the intervention and thereby enabling decisive therapeutic modifications to be performed in a timely fashion. Consequently, TCD monitoring has a significant role in detecting intracranial blood flow changes during carotid endarterectomy (CEA), surgical management of ruptured aneurysms causing subarachnoid haemorrhage (SAH), open heart surgery with and without the use of extracorporeal circulation (ECC), and thrombolytic therapy for acute ischemic stroke.

METHODS

TCD monitoring of cerebral circulation is performed by 2 MHz probes of 20–60 mm diameter. We have previously used the Translink 8000 EME ultrasonic device, Rimed, Israel, and, more recently the Looki, Atys Medical, France, with 2 MHz probes that are placed on the temporal acoustic window to record blood flow in the MCA. The option of focusing the ultrasound beam (sample volume) in different depths from the temporal acoustic window allows us to detect Doppler signals from individual basal cerebral arteries. The TCD device enables frequency spectral analysis and colour coded blood flow and, addition-

ally, shows two different colored curves simultaneously, representing peak systolic velocity and mean flow velocity in a specific brain artery. The Looki Atys Medical has sophisticated software for detecting cerebral microembolisms. Among all the spectral parameters of flow, the MFV has the most important physiological significance. It also has a better correlation with cerebral perfusion values than peak velocity, which is why MFV is used for detecting the TCD signal (2).

The technique of TCD monitoring

The temporal acoustic window is used to monitor cerebral blood flow. 2 MHz probes need to be fixed manually, although there are different frames and tapes available for fixing probes. There is also the option of using a bi-directional approach but this is mostly not feasible during surgery, due to movement of the head. Between surgical interventions, we have to prevent the movement and maintain an optimal signal by manually setting the probe, which can be quite difficult and requires investigator experience.

In the cases of CEA and carotid angioplasty with stenting (CAS), we monitor flow in the ipsilateral MCA. During the neurosurgical intervention, the probe is placed on the opposite side of the craniotomy, thus increasing the depth of the ultrasound beam that can track flow in the arteries on the side opposite to the surgery.

Carotid endarterectomy – CEA

It is very important to determine the cerebrovascular reserve (CVR) before surgery. Piepgrass et al. reported that a simple and reliable method of determining the preoperative CVR is to check for an MFV increase following stimulation with 1 g acetazolamide (4).

It is also important to detect "tandem lesions" preoperatively; these are simultaneous extracranial and

intracranial stenoses in the carotid system on the same side, and such stenoses are a contraindication for CEA (5).

Intraoperative TCD monitoring of blood flow in the MCA during CEA provides important information about changes of intracranial hemodynamics during certain phases of surgery (6). It provides insight into the functional performance of the collateral circulation and the effects of the CEA. Hemodynamic changes in the MCA during CEA are analysed by a modified scheme, which was first proposed by Padayachee et al. (2). MFV and the pulsatility index (PI) in the MCA are analysed in the following phases:

1. before surgery,
2. at anaesthesia induction,
3. during preparation of the bifurcation,
4. while clamping the external carotid artery (ECA), internal carotid artery (ICA), and common carotid artery (CCA),
5. when placing the intraluminal shunt,
6. when declamping,
7. at the end of surgery,
8. during patient awakening,
9. 30 minutes after awakening.

The riskiest phase of CEA is primarily while clamping the CCA. If TCD shows complete interruption or severe hypoperfusion (MFV < 20 cm/s) of the flow in the MCA after clamping (5), it is necessary to induce an intraluminal shunt urgently (7). In cases where the MFV remains stable and does not fall below 27 cm/s in the MCA, safe surgery without the use of an intraluminal shunt (2) is possible (Fig. 1). Approximately two-thirds of patients do not require a shunt (8). However, when an intraluminal shunt is used, experience shows that the insertion itself is a risk factor for brain damage because of the potential for cerebral thromboembolism, which may result from thrombus detachment caused by inserting the shunt. TCD can monitor for side effects and can also confirm the success of the shunt. If after its insertion hypoperfusion persists or signs of cerebral microembolisms appear, prompt repositioning of the shunt is required (2).

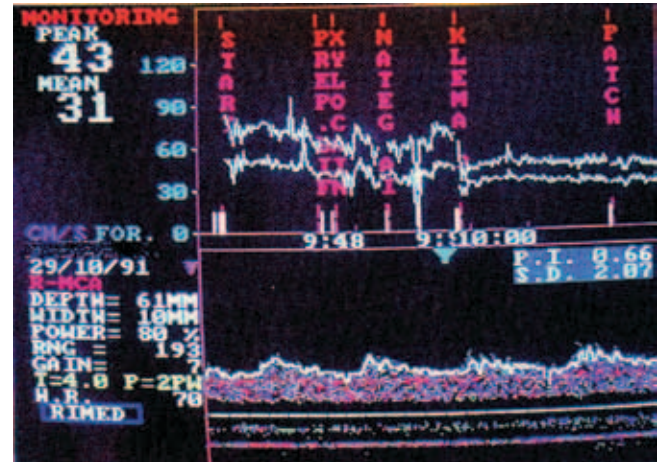

Fig. 1. TCD monitoring shows almost normal flow in the MCA after clamping the common carotid artery: the small reduction in MFV (in green) allows surgery without intraluminal shunt.

Declamping the carotid may lead to cerebral microembolisms, registered as short-term high-intensity signals known as HITS (high intensity transient signals). During surgery, early detection of the initial vasospasm in the MCA and neighboring branches, reflected by an increase in the MFV, is very important. Immediate application of nimodipine can prevent generalized vasospasm.

Recently, TCD monitoring has also been shown to have a significant role in identifying intraoperative and early postoperative hyperperfusion syndrome (HPS). An MFV increase in the MCA above 90 cm/s for more than 3 minutes is highly suspicious for early HPS. This sometimes fatal complication results mainly from unstable arterial hypertension (9, 10).

Carotid angioplasty with stenting – CAS

In 1979 Mathias performed the first carotid angioplasty, in a 32-year-old patient with fibromuscular dysplasia, and in 1980 he operated on a symptomatic patient with atherosclerotic stenosis of the ICA (11). The use of stents has opened the possibility of dilating ulcerated and partly thrombosed stenoses.

Modern vascular stents are specially prepared for insertion into the carotid artery and it is possible to successfully resolve over 90% carotid stenoses with a low risk of complications (12). The risks were further reduced by the introduction of distal protection with protective balloons and filters, which intercept emboli before they reach the brain (the protective filter is set above the area of narrowing). Another potential approach to protecting the brain is proximally, if the common carotid artery below the stenosis is occluded and the blood flow is reversed so that during dilatation, released emboli do not flow through the guide-way toward the brain. The first carotid angioplasty without brain protection in Slovenia was performed in the year 2000 and the first to use a distal protecting filter took place in February 2001 (13).

The rate of complications in CAS is at least as high as in CEA and neurological complications include HPS, TIA, and mild or severe stroke. Intraoperative and early postoperative TCD monitoring of flow in the ipsilateral MCA provides important insights into changes in the cerebral hemodynamics. During balloon dilatation or stent insertion, we rarely detect signs of cerebral (micro)embolisms because of the use of distal or proximal protections for the brain. Even after the removal of protection, we only rarely

detect cerebral microembolisms. However, early after stenting (days to weeks after the procedure) it is not uncommon to detect the characteristics of HPS (Fig. 2, 3).

Later TCD monitoring of flow in the MCA (1, 3, and 6 months and 1 year after the procedure) reveals the functional performance of the stent. Cerebral hypoperfusion suggests restenosis or even occlusion of the artery, although this is rare. Restenosis needs to be resolved with re-dilatation.

Coronary artery bypass grafting

Since 1970, when Favalaro published the results of coronary artery bypasses using extracorporeal circulation (ECC), this method has become highly recognized and a standard in open heart surgery. Although the majority of surgical patients in the past were treated using the ECC "on pump" method, recently more procedures are being done using an active heart "off pump" method. The cause of postoperative neurological complications, including postoperative cognitive deficit (PCD), is brain microembolisms. In 1990, Pugsley described a causal link between the number of reg-




Fig. 2. 3D ultrasonography shows the ICA 6 months after stenting. A stent successfully dilates the ICA stenosis.

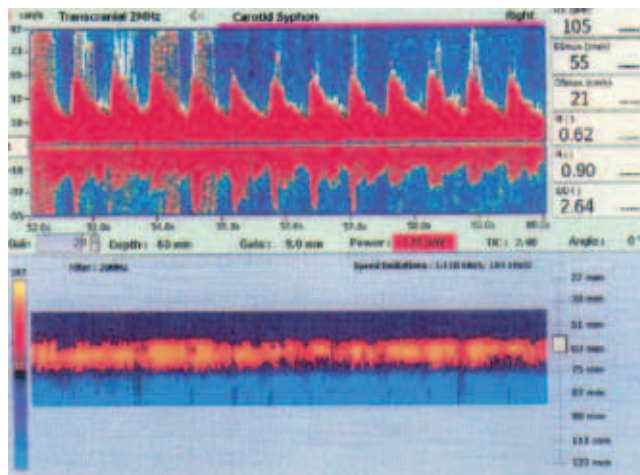


Fig. 3. TCD shows normal flow in the ICA syphon immediately after stenting.

istered HITS and the incidence of PCD (14). Intraoperative bidirectional TCD monitoring of blood flow, particularly in the MCA, allows reliable TCD recording of HITS. Macroembolisms usually cause stroke (15) and it is microembolisms that are more often responsible for PCD, which may occlude small diameter blood vessels.

HITS, which is characterized by a duration of < 0.1 s, an intensity usually of > 8 dB, and a typical high pitched sound, occurs most frequently during manipulation of the aorta (16). In support of the findings of Barbut, Jacobs et al. found that 71.3% of all HITS occur in patients undergoing the "on pump" method, a figure that is substantially greater than that in patients having the "off pump" method (17). They also found that the frequency of HITS was different in various stages of the surgery, with the highest being with particular instrumental procedures on the aorta, namely:

- cannulating the aorta 3.6%,
- cross clamping the aorta 3.7%,
- cross declamping 5.0%,
- partial clamping 0.9%,
- when opening the bypasses 4.6% (17) (Fig. 4).

The most common cause of cerebral microembolisms with the "on pump" method is atherosclerotic change in the aortic wall, either in the aortic arc or in the ascending aorta, and Hartman et al. established a casual link between atherosclerotic changes in the aortic wall, identified by transesophageal echocardiography (TEE), and postoperative neurological complications. It has been found that stroke is more frequent with more severe aortic atherosclerosis (level III, IV) and PCD more often occurs with milder changes (I, II), mostly thickening of the intima-media (IMT) (18). Barbut et al. investigated intraoperative TCD and TEE and found that during the "on pump" method 84% of all HITS occurred during cross clamping and cross declamping of the aorta: a majority of cases of HITS occurred in the first 10 seconds after aortic declamping (19). TEE of the ascending aorta just before the intervention allows the selection of optimal places in the aorta for installing the aortic cannula or clamp (20). Some surgeons currently evaluate the

effect of a special filter inserted into the aorta before cross clamping for neuroprotection. On the surface of such filters, atheroma and fibrous tissues are found in 62% of cases and other particles, such as a fibrin, in 52% (21).

In addition to detecting intraoperative embolisms, it is very important to detect diffuse brain hypoperfusion, especially with the "on pump" method. It is an important cause of postoperative neurological disorders, especially PCD. Prolonged brain hypoperfusion with values of MFV below 27 cm/s in the MCA trigger an ischemic cascade, which may lead to the death of brain cells. In the "off pump" method, hypoperfusion rarely occurs. In the case of manipulation of the heart (rotation, elevation), profound short-term hypoperfusion can occur, sometimes with complete interruption of the blood flow, but flow often quickly returns to normal when the manipulation ceases (22, 23, 24) (Fig. 5).

Surgery for ruptured aneurysms causing SAH

One of the most serious complications of aneurysmal SAH is undoubtedly spasm of the basal cerebral arteries. According to data from several different au-

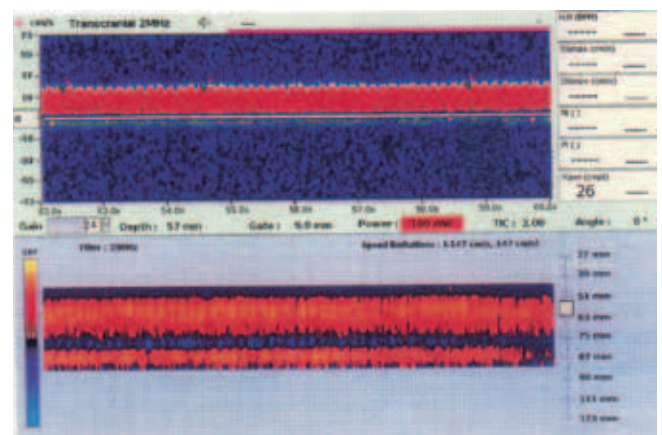


Fig. 4. TCD monitoring reveals mild hypoperfusion in the MCA during on-pump surgery of the coronary bypass grafting.

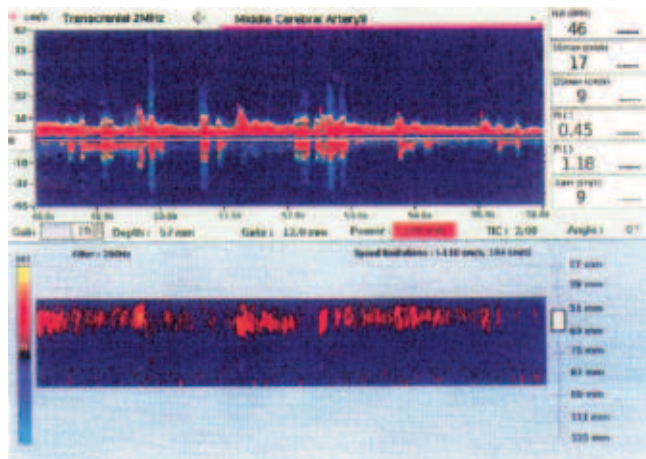


Fig. 5. TCD shows minimal residual flow in the MCA during off-pump surgery of the coronary bypass grafting.

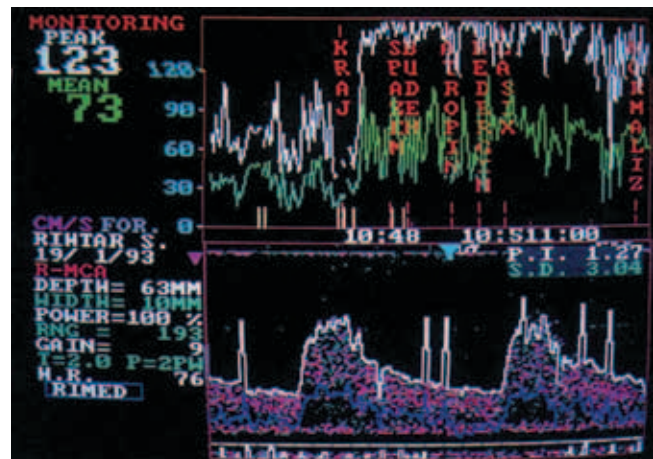


Fig. 6. TCD shows initial vasospasm in the MCA at the end of the ruptured aneurysm surgery in SAH.

thors, the incidence is up to 55% (25). Olafsson put the mortality rate from ischemic brain damage in chronic cerebral hypoperfusion at 47% (26). Early intraoperative identification of initial vasospasm is important because it allows immediate and appropriate therapy to be given. The advantage of TCD monitoring of cerebral blood flow is that it directly shows changes in brain hemodynamics and allows treatment (Fig. 6).

Thrombolytic therapy

To evaluate hemodynamic changes in the occluded MCA during thrombolysis, the TIBI scale (Thrombolysis In Brain Ischemia) is used. Flow in the MCA detected by TCD is divided into 6 grades: grade 0: absent flow, grade 1: minimal, barely perceptible, grade 2: fairly reduced (attenuated), grade 3: dampened, grade 4: stenotic, grade 5: normal (27).

Complete recanalization can occur even if TCD shows minimal flow (28). Complete recanalization occurs in 30%, and partial recanalization in 40% of thrombolized patients. Dramatic clinical improvement, which is always associated with complete recanalization, occurs in 20% of patients (29).

CONCLUSION

Intraoperative and early postoperative TCD monitoring of cerebral blood flow during CEA, CAS, coronary artery bypass surgery, and surgery for ruptured aneurysms causing SAH provides important information about changes in brain hemodynamics that enables immediate and appropriate therapy to be given. This may help reduce perioperative morbidity and mortality. TCD monitoring has also a significant role during thrombolysis.

References:

1. Nornes H, Grip A, Wickeby P. Intraoperative evaluation of cerebral hemodynamics using directional Doppler technique, Part 2. Saccular aneurysms. *J Neurosurg* 1979; 5:570 – 7.
2. Tetičkovič E, Intraoperativni TCD. In: Tetičkovič E, ed. *Dopplerjeva sonografija možganskega ožilja*. Maribor: Založba Obzorja in Grafično založniško podjetje Mariborski tisk, 1992: 119 – 32.
3. Karnik R, Valentin A, Bonner G, Ziegler B, Slany J. Transcranial Doppler monitoring during percutaneous transluminal aortic valvuloplasty. *Angiology* 1990; 2: 106 – 11.
4. Piepgras A, Schmiedek P, Leinsinger G, Haberl RL, Kirsch CM, Einhüpl KM A simple test to assess cerebrovascular reserve capacity using transcranial Doppler sonography and acetazolamide. *Stroke* 1990; 21(9): 1306 – 11.
5. Bernstein EF. Role of transcranial Doppler in carotid surgery. *Surg Clin North Am* 1990; 70: 225 – 34.
6. Demarin V, Transkranijski dopler (TCD). In: Demarin V, Štikovac M, Thaller N, eds. *Doppler sonografija krvnih žila*. Zagreb: Školska knjiga, 1990: 89 – 129.
7. Chiesa R, Minicucci F, Melissano G, Truci G, Comi G, Paolillo G, Grossi A. The role of transcranial Doppler (TCD) in carotid artery surgery. *Eur J Vasc Surg* 1992; 6: 211– 6.
8. Ferguson F. Intraoperative monitoring and internal shunts. Are they necessary in carotid endarterectomy. *Stroke* 1988; 13: 287 – 9.
9. McCabe DJH, Brown MM, Clifton A. Fatal cerebral reperfusion hemorrhage after carotid stenting. *Stroke* 1999; 30: 2483 – 6.
10. Tetičkovič E. Transkranialna Dopplerjeva sonografija – TCD pri ugotavljanju možganskega hiperperfuzijskega sindroma po karotidni endarterektomiji in karotidni angioplastiki s stentiranjem. In: Tetičkovič E, Žvan B. *Možganska kap – do kdaj*. Maribor: Kapital, 2007: 125 – 31.
11. Mathias K, Jager H, Hennings S. Endoluminal treatment of internal carotid stenosis. *World Surg* 1982; 25: 328 – 36.
12. Wholey MH, Wholey M, Bergeron P, Diethrich EB, Henry M, Laborde JC et al. Current global status of carotid artery stent placement. *Cathet Cardiovasc Diagn* 1998; 44: 1 – 6.
13. Milošević Z, Kocijančič J, Zaletel M, Žvan B. Karotidna angioplastika z vstavitvijo žilne opornice. In: Tetičkovič E, Žvan B, eds. *Sodobni pogledi na možganskožilne bolezni*. Maribor: Obzorja, 2003: 181 – 6.
14. Pugsley W, Klinger J, Paschalis C. Microemboli and cerebral impairment during cardiac surgery. *Vasc Surg* 1990; 24: 34 – 43.
15. Mizuno T, Toyama M, Tabuchi N, Kuriu K, Ozaki S, Kawase I et al. Thickened intima of the aortic arch is a risk factor for stroke with coronary artery bypass grafting. *Ann Thorac Surg* 2000; 70: 1565 – 70.
16. Barbut D, Hinton RB, Szatrowski TP, Hartman GS, Bruefach M, Williams-Russo P et al. Cerebral emboli detected during bypass surgery are associated with clamp removal. *Stroke* 1994; 25: 2398 – 402.
17. Jacobs A, Neveling M, Horst M, Ghaemi M, Kessler J, Eichstaedt H et al. Alterations of neuropsychological function and cerebral glucose metabolism after carotid surgery are not related only to intraoperative microembolic events. *Stroke* 1998; 29: 660 – 7.
18. Hartman GS, Yao FF, Bruefach M 3rd, Barbut D, Peterson JC, Purcell MH et al. Severity of aortic atheromatous disease diagnosed by transesophageal echocardiography predicts stroke after outcomes associated with coronary artery surgery: A prospective study. *Anesth Analg* 1996; 83: 701 – 8.
19. Barbut D, Yao FS, Hager DN, Kavanaugh P, Trifiletti RR, Gold JP. Comparison of transcranial Doppler ultrasonography and transesophageal echocardiography to monitor emboli during coronary artery bypass surgery. *Stroke* 1996; 27: 87 – 90.
20. Sylvris S, Levic G, Matalaris G, Rosalion A, Buxton BF, Mitchell A et al. Pattern and significance of cerebral microemboli during coronary artery bypass grafting. *Ann Thorac Surg* 1998; 66: 1674 – 8.

21. Tetičkovič E, Košir G, Felser Rakovec Z, Bobičič R, Magdič J. Medoperativno ultrazvočno spremljanje možganskega krvnega pretoka in pooperativno ugotavljanje kognitivne disfunkcije pri operacijah z aorto-koronarnimi obvodi. In: Tetičkovič E, Žvan B, eds. *Sodobni pogledi na možganskožilne bolezni*. Maribor: Obzorja, 2003: 63 – 75.
22. Puskas JD, Winston D, Wright CE, Gott JP, Brown WM 3rd, Craver JM et al. Stroke after coronary artery operation: incidence, correlates, outcome and cost. *Ann Thorac Surg* 2000; 69: 10053.
23. John R, Choudhri AF, Weinberg AD, Ting W, Rose EA, Smith CR et al. Multicenter review of perioperative risk factors for stroke after coronary bypass grafting. *Ann Thorac Surg* 2000; 69: 30.
24. Košir G. Revaskularizacija srca in obolenje karotid. In: Tetičkovič E, Žvan B, eds. *Možganska kap – do kdaj*. Maribor: Kapital, 2007: 235 – 8.
25. Tetičkovič E. Medoperativno ugotavljanje spazma bazalnih možganskih arterij s transkranialno Dopplerjevo sonografijo pri anevrizmatskih subarahnoidnih krvavitvah. *Med Razgl* 1999; 38: Suppl 5: 97 – 104.
26. Olafsson E, Hanser A, Gudmundsson G. A population-based study of subarachnoid haemorrhage. *Neurology* 1997; 48: 1191 – 5.
27. Demchuk AM, Burgin WS, Christou J, Felberg RA, Barber PA, Hill MD et al. Thrombolysis in brain ischemia (TIBI). Transcranial Doppler flow grades predict clinical severity, early recovery, and mortality in patients treated with intravenous tissue plasminogen activator. *Stroke* 2001; 32: 89 – 105.
28. Labiche LA, Malkoff M, Alexandrov AV. Residual flow signals predict complete recanalization in stroke patients treated with tPA. *J Neuroimaging* 2003; 13: 28 – 33.
29. Tetičkovič E, Menih M. Trombolitično zdravljenje in dramatično izboljšanje klinične slike pri bolniku z akutno zaporo srednje možganske arterije, spremljano s transkranialno Dopplerjevo sonografijo. *Zdrav Vestn* 2004; 73: 235 – 8.