

# Gostota malih žil in vrednosti PSA pri adenokarcinomih prostate z oceno 6 in 7 po Gleasonu

## Microvessel density and PSA level in prostatic adenocarcinoma of Gleason score 6 and 7

Avtor / Author

Ustanova / Institute

Barbara Dariš<sup>1</sup>, Miha Munda<sup>2</sup>

<sup>1</sup>Univerza v Mariboru, Medicinska fakulteta, Inštitut za biomedicinske vede, Maribor, Slovenija;

<sup>2</sup>Univerza v Mariboru, Medicinska fakulteta, Katedra za histologijo in embriologijo, Maribor, Slovenija

<sup>1</sup>University of Maribor, Faculty of Medicine, Institute of Biomedical Sciences, Maribor, Slovenia; <sup>2</sup>University of Maribor, Faculty of Medicine, Department of Histology and Embryology, Maribor, Slovenia

### Ključne besede:

adenokarcinom prostate, angiogeneza, gostota malih žil, endoglin, imunohistokemija.

### Key words:

prostatic adenocarcinoma, angiogenesis, microvessel density, endoglin, immunohistochemistry.

### Članek prispel / Received

26. 4. 2018

### Članek sprejet / Accepted

10. 7. 2018

### Naslov za dopisovanje / Correspondence

Asist. dr. Barbara Dariš

Univerza v Mariboru, Medicinska fakulteta, Inštitut za biomedicinske vede

Taborska 8, 2000 Maribor

Telefon: +386 23305875

E-pošta: barbara.daris@um.si

### Izvleček

**Namen:** Želeli smo ugotoviti, ali se pri bolnikih z adenokarcinomom prostate z oceno 6 in 7 po Gleasonu razlikujeta gostota malih žil v tumorjih in vrednosti prostatičnega specifičnega antigena (PSA).

**Metode:** V raziskavo je bilo vključene 100 bolnikov z adenokarcinomom prostate, ki smo jih razdelili v dve skupini glede na oceno po Gleasonu (GS). V prvi skupini je bilo 52 bolnikov z GS 6, v drugi pa 48 bolnikov z GS 7. S protitelesi za endoglin smo raziskali ožiljenost znotraj tumorja. Endoglin je specifičen označevalec za novo nastale žile v in okrog tumorskega tkiva, ne pa za žile v netumorskem tkivu. Na vsakem histološkem preparatu smo določili območja največje gostote malih žil in le-te prešteli pri 400-kratni povečavi (površina 0,19 mm<sup>2</sup>).

**Rezultati:** Skupina vzorcev z GS 6 ni imela značilno različne gostote žil v vidnem polju (24,5 vs. 29,0;  $P = 0,46$ ) oz. gostote žil, preračunane na mm<sup>2</sup> tu-

### Abstract

**Purpose:** The aim of this investigation was to determine the differences in microvessel density (MVD) and serum levels of prostate-specific antigen (PSA) between groups of patients with Gleason score (GS) 6 prostatic adenocarcinoma and patients with GS 7 prostatic adenocarcinoma.

**Methods:** The study included a series of 100 patients with prostatic adenocarcinoma. Tumor specimens were divided into two groups: GS 6 (52 cases) and GS 7 (48 cases). Intratumoral microvasculature was determined by immunohistochemistry using an antibody against endoglin. Endoglin stained microvessels were observed in and around the tumor, but weak or no staining of blood vessels was seen in non-neoplastic tissue. Areas of maximal angiogenesis within the tumor were identified and microvessels were counted at  $\times 400$  magnification (0.19 mm<sup>2</sup> field).

**Results:** The GS 6 specimens did not significantly differ in MVD per field

morskega tkiva (109,3 vs. 129,6;  $P = 0,78$ ), v primerjavi s skupino vzorcev z GS 7. Skupini se nista razlikovali glede na vrednost PSA (8,5 vs. 10,1 ng/mL;  $P = 0,66$ ). Gostota malih žil v tumorjih ni bila povezana z vrednostjo PSA ( $r = 0,1$ ;  $P = 0,62$ ). Skupini bolnikov se nista razlikovali v starosti (63,0 vs. 65,0 let;  $P = 0,84$ ).

**Zaključek:** Rezultati raziskave kažejo, da se adenokarcinomi prostate z oceno 6 in 7 po Gleasonu ne razlikujejo v neovaskularizaciji in tudi ne v vrednostih PSA.

(24.5 vs. 29.0;  $P=0.46$ ) or MVD per mm<sup>2</sup> (109.3 vs. 129.6;  $P=0.78$ ) when compared with the GS 7 specimens. No significant difference in mean serum levels of PSA between the two groups was observed (8.5 vs. 10.1 ng/mL;  $P=0.66$ ). MVD per mm<sup>2</sup> was not correlated with PSA ( $r=0.1$ ;  $P=0.62$ ). The age of patients at diagnosis was not significantly different between the two groups (63.0 vs. 65.0 years;  $P=0.84$ ).

**Conclusion:** Our results show no significant differences in neovascularization and PSA level between Gleason score 6 and 7 prostatic adenocarcinoma.

## INTRODUCTION

Prostatic adenocarcinoma is the most commonly diagnosed male malignancy and its incidence is growing (1, 2). Parameters that can stratify patients for type of therapy based on the likelihood of tumor progression are clinical stage, serum level of prostate-specific antigen (PSA) and histological differentiation, which is conventionally reported as the Gleason score (3, 4). Approximately 80% of men diagnosed with prostate cancer have moderately increased serum levels of PSA (3–10 ng/mL) and a non-palpable localized tumor with a Gleason score of 6 or 7 (GS 6 or 7) (5, 6). However, elevated serum PSA levels can be detected in non-tumor disease, including benign prostate hyperplasia and prostatitis (1). Furthermore, for patients with an intermediate GS (GS 6 and GS 7), accurate predictions of outcome are often difficult (1). Therefore, many investigators pay special attention to tumor markers and predictive factors in patients with prostatic adenocarcinoma.

Angiogenesis is the formation of new blood vessels from pre-existing vessels and has an important role in the progression and metastasis of tumors (7). The most common method for semi-quantitative evaluation of angiogenesis is the measurement of microvessel density (MVD) using endothelial markers (8). Endoglin (CD 105) is a transforming growth factor 1 receptor. It is expressed on endothelial cells during tumor angiogenesis and inflammation with weak or negative expression in the vascular endothelium of normal tissue (8-11). MVD evaluation determined

using anti-endoglin monoclonal antibodies has been shown to be an independent prognostic factor for certain types of malignant neoplasia, such as breast carcinoma and non-small-cell lung carcinoma (12, 13). Nevertheless, its significance in prostatic adenocarcinoma is controversial, as some studies proved a correlation between MVD and both tumor progression and survival (9, 14-18), while others failed to confirm the prognostic value of MVD (1, 19-21).

The aim of the present study was to determine possible differences in MVD (assessed by analyses of endoglin immunoreactivity) and serum levels of PSA between groups of patients with GS 6 prostatic adenocarcinoma and patients with GS 7 prostatic adenocarcinoma. Here we present the final results of the first study of endoglin expression in prostatic adenocarcinoma in subjects living in Slovenia.

## MATERIALS AND METHODS

The 105 radical prostatectomy tissue specimens were re-examined. Of these, 100 were considered suitable for the study (paraffin blocks intact, enough material for re-cutting, complete baseline clinical and follow-up data). The median age of the patients at diagnosis was 65 (range 44–74) years. The specimens were divided in two groups: GS 6 (52 cases) and GS 7 (48 cases). Paraffin-embedded biopsy tissue blocks were cut into 4- $\mu$ m sections, deparaffinized, and rehydrated.

Antigenic recovery was achieved by heating the slides in an autoclave with sodium citrate buffer (30 min). Endogenous peroxidase was inhibited with a Peroxidase Block Kit (Novocastra Laboratories, Newcastle upon Tyne, UK). Immunohistochemical staining was undertaken using primary antibodies against endoglin (1:50 dilution; Novocastra Laboratories). A Novolink Polymer Detection System (Novocastra Laboratories) was used for visualization. Primary antibodies were omitted in negative controls. Sections of tonsil tissue were used as positive controls. Tissue sections were counterstained using Mayer's hematoxylin and mounted. Immunoreactivity was evaluated without knowledge of patient data. After scanning the immunostained section at low magnification ( $\times 40$ ), three areas of maximal angiogenesis ("hotspots") within the tumor were identified. Microvessels were then counted at  $\times 400$  magnification (0.19 mm<sup>2</sup> field). Any single cell or spot stained by the immunohistochemical marker was counted as a vessel. As in previous reports (9, 12, 17), a visible vascular lumen was not required to count as a microvessel. The highest number of vessels counted in any hotspot was recorded (MVD per field). The mean vascular count per mm<sup>2</sup> was then calculated (MVD per mm<sup>2</sup>). Both values were used in the statistical analysis. The groups were compared using the Student's *t*-test for independent samples. Correlations were calculated using Pearson's correlation test.  $P < 0.05$  was considered significant. Statistical analyses were carried out using IBM SPSS (Version 25.0. IBM Corp., Armonk, NY, USA).

## RESULTS

The group of specimens with GS 6 had lower MVD per field than the group with GS 7 (24.5 vs. 29.0;  $P=0.46$ ; Table 1), but this difference was not significant. The same was true when MVD per mm<sup>2</sup> was compared between the two groups (109.3 vs. 129.6;  $P=0.78$ ; Table 1). Endoglin expression in GS 6 and GS 7 specimens is shown in Figures 1 and 2, respectively. The preoperative serum level of PSA was 1.4–69.5 ng/mL in the GS 6 group (median, 5.7 ng/mL), and 0.3–34.4 ng/mL in the GS 7 group (median, 8.1 ng/mL; Figure 3). The mean PSA level in serum was not

significantly different in the GS 6 group compared with the GS 7 group (8.5 vs. 10.1 ng/mL;  $P=0.66$ ; Table 1). MVD per mm<sup>2</sup> was not correlated with PSA ( $r=0.1$ ;  $P=0.62$ ). The age of patients at diagnosis was not significantly different in the two groups (63.0 vs. 65.0 years;  $P=0.84$ ; Table 1).

## DISCUSSION

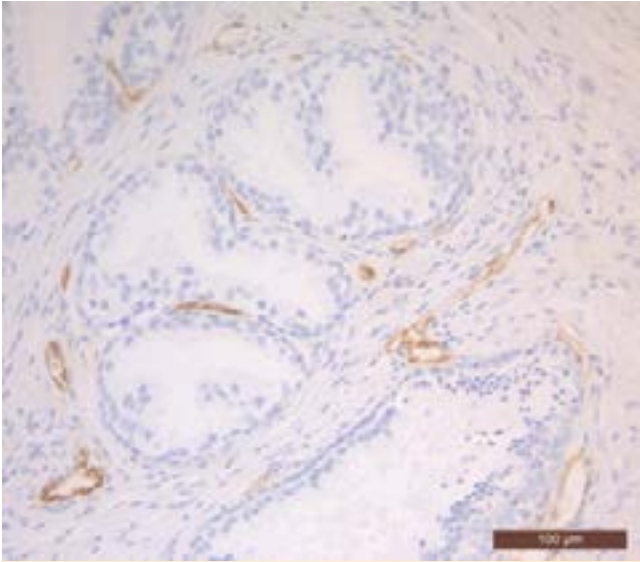
In this study, we investigated angiogenesis in GS 6 and GS 7 specimens, currently the most commonly assigned Gleason scores in prostatic adenocarcinomas (4). Angiogenesis plays an important role in tumor growth and cancer cell dissemination. The association between increasing tumor vascularity and various measures of tumor aggressiveness (such as a greater incidence of metastases and/or reduced patient survival) has been shown in studies of patients with various types of carcinoma (12, 13, 15, 22–24). Our results showed no significant difference in MVD in GS 6 specimens compared with GS 7 specimens. Some studies have shown a correlation between Gleason score and MVD (9, 16–19, 25), whereas others have not (1, 20, 26–28). This discrepancy may have been due to the different methodology used to assay MVD in the above-mentioned studies. It has been

**Table 1:** Comparison of GS 6 and GS 7 specimens

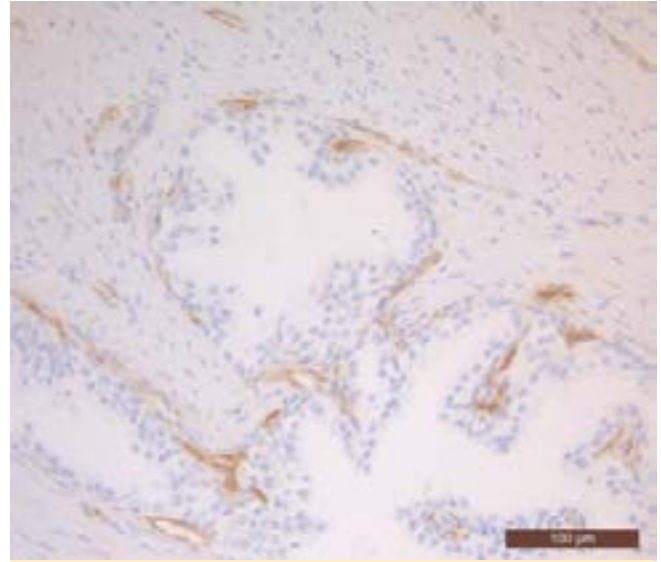
	GS 6 (n=52) Mean $\pm$ SD	GS 7 (n=48) Mean $\pm$ SD	P value
MVD per field	24,5 $\pm$ 13,5	29,0 $\pm$ 13,9	0,46
MVD per mm <sup>2</sup>	109,3 $\pm$ 58,2	129,6 $\pm$ 64,7	0,78
PSA (ng/mL)	8,5 $\pm$ 11,1	10,1 $\pm$ 8,2	0,66
Age of patients (years)	63,0 $\pm$ 5,3	65,0 $\pm$ 6,4	0,84

GS = Gleason score; SD = standard deviation; MVD = microvessel density; PSA = prostate-specific antigen

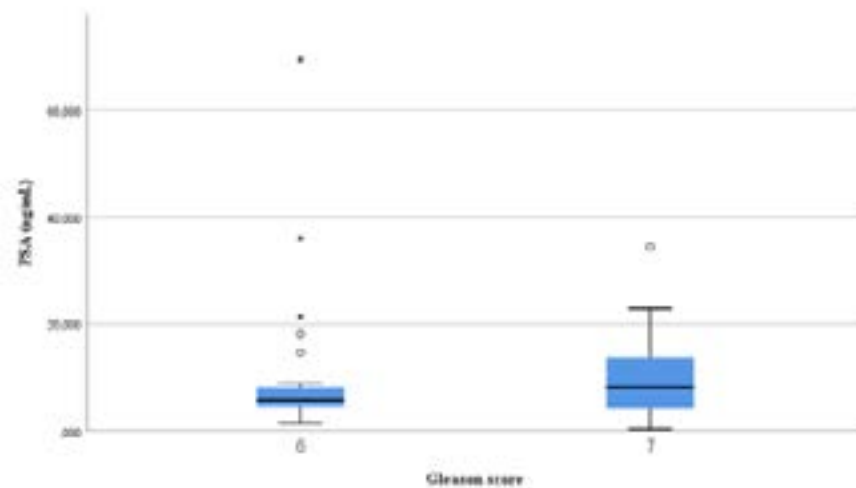
reported that the choice of antibody (e.g., CD31, CD34, von Willebrand factor (vWF), endoglin) can influence study outcome (29). Although CD31, CD34, and vWF do not stain all microvessels, and particularly not newly formed microvessels (9, 17, 25),



**Figure 1.** Immunohistochemical endoglin expression in GS 6 specimen



**Figure 2.** Immunohistochemical endoglin expression in GS 7 specimen



**Figure 3.** Preoperative PSA level in GS 6 and GS 7 cases (median 5.7 vs. 8.1 ng/mL;  $P = 0.8$ )

several authors used these antibodies (14, 16, 18, 19, 26, 28). In the present study, we used endoglin, which was consistently present in all cases and which stained microvessels in and around the tumor, but showed weak or no staining of blood vessels in non-neoplastic tissue. Studies also differed with regard to the quantification of angiogenesis, as most authors examined areas of maximal angiogenesis (hotspots) at  $\times 200$  magnification (6, 9, 16, 18, 19, 25). In the present study, we evaluated angiogenesis at  $\times 400$  magnification, which

allowed more precise quantification of the number of vessels than if we had evaluated MVD at  $\times 200$  magnification. Only a few reports determined MVD at  $\times 400$  magnification (14, 17, 28). Furthermore, in the statistical analyses we used two series of data for each specimen: MVD per field and MVD per mm<sup>2</sup>. Nevertheless, according to our results GS 6 and GS 7 specimens do not differ in the angiogenic status of cancer tissue. Two recent research studies also failed to prove MVD as a prognostic factor in prostatic adenocarcinoma

(1, 20). No correlation between MVD and serum levels of PSA was observed in the present study. This finding is in agreement with those in other reports (19, 25, 27, 28). Furthermore, a significant difference was not shown when serum levels of PSA between the two groups of patients in the present study were compared. One reason for this is the degree of dispersion of the data. PSA is a key variable in prognostic models for clinically localized prostate cancer. It is used to assess pathological tumor stage and the risk of disease recurrence after local therapy. However, elevations in

PSA serum levels do not solely reflect the presence of cancer, but may also be driven by certain non-malignant causes such as nodular hyperplastic changes in the prostate gland, and prostatic inflammatory processes (30). In fact, PSA is not a cancer-specific but an organ-specific marker (31). Several studies have reported the limitations and inconsistency of PSA as a diagnostic and prognostic marker for prostate cancer (25-28, 30-33). Consequently, other PSA-based strategies are being tested for clinical use, such as PSA density (ratio of an individual serum PSA level and its corresponding prostate volume as assessed by transrectal ultrasonography), percent free PSA (%fPSA; calculated from analyzed free PSA and total PSA) and complexed PSA (bound to plasma proteins). Of these, only %fPSA is already used in the clinic (30). Furthermore, several alternative biomarkers of the cell cycle, cell invasion, cell adhesion, signal transduction, apoptosis, angiogenesis, and genetic biomarkers have

been suggested to supplement or even replace PSA to improve strategies for early detection and predict the natural behavior of the tumor (31, 33).

In summary, our results showed that GS 6 and GS 7 prostate tumors do not significantly differ in MVD and serum levels of PSA. Although MVD has already been found to be a prognostic factor in several malignancies, this is still controversial in prostatic adenocarcinoma. One of the reasons for this is that a standard method with high reliability and reproducibility has not yet been established. Furthermore, new information regarding markers and antibodies for cancer-specific endothelial cells has increased in recent years. Taken together, these findings suggest that more detailed studies with large numbers of specimens and a precise methodology for evaluating angiogenesis are needed to understand the pathological role of angiogenesis in prostatic adenocarcinoma and elucidate the possible prognostic value of MVD.

## REFERENCES

- Miyata Y, Sakai H. Reconsideration of the clinical and histopathological significance of angiogenesis in prostate cancer: Usefulness and limitations of microvessel density measurement. *Int J Urol* 2015; 22: 806-15.
- Van Moorselaar RJA, Voest EE. Angiogenesis in prostate cancer: its role in disease progression and possible therapeutic approaches. *Mol Cell Endo* 2002; 197: 239-50.
- Garcia FU, Taylor CA, Hou S, Rukstalis DB, Stearns ME. Increased cellularity of tumor-encased native vessels in prostate carcinoma is a marker for tumor progression. *Mod Pathol* 2000; 13: 717-22.
- Humphrey PA. Gleason grading and prognostic factors in carcinoma of the prostate. *Mod Pathol* 2004; 17: 292-306.
- Schroder FH, van der Crujisen-Koeter I, de Koning HJ, Vis AN, Hoedemaeker RF, Kranse R. Prostate cancer detection at low prostate specific antigen. *J Urol* 2000; 163:806-12.
- Josefsson A, Wikstöm P, Granfors T, Egevad L, Karlberg L, Stattin P et al. Tumor size, vascular density and proliferation as prognostic markers in GS 6 and GS 7 prostate tumors in patients with long follow-up and non-curative treatment. *Eur Urol* 2005; 48: 577-83.
- Offersen BV, Borre M, Overgaard J. Quantification of angiogenesis as a prognostic marker in human carcinomas: a critical evaluation of histopathological methods for estimation of vascular density. *Eur J Cancer* 2003; 39: 881-90.
- Miyata Y, Sagara Y, Watanabe S, Asai A, Matsuo T, Ohba K et al. CD105 is a more appropriate marker for evaluating angiogenesis in urothelial cancer of the upper urinary tract than CD31 or CD34. *Virchows Arch* 2013; 463: 673-9.
- Wikström P, Lissbrant IF, Stattin P, Egevad L, Bergh A. Endoglin (CD 105) is expressed on immature blood vessels and is a marker for survival in prostate cancer. *Prostate* 2002; 51: 268-75.
- Bernabeu C, Conley BA, Vary CPH. Novel biochemical pathways of endoglin in vascular cell

- physiology. *J Cell Biochem* 2007; 102: 1375-88.
11. Fujita K, Ewing CM, Chan DYS, Mangold LA, Partin AW, Isaacs WB et al. Endoglin (CD 105) as a urinary and serum marker of prostate cancer. *Int J Cancer* 2009; 124 (3): 664-9.
  12. Netto GC, Bleil CB, Hilbig A, Coutinho LMB. Immunohistochemical evaluation of the microvascular density through the expression of TGF- (CD 105/endoglin) and CD 34 receptors and expression of the vascular endothelial growth factor (VEGF) in oligodendrogliomas. *Neuropathology* 2008; 28: 17-23.
  13. Sharma S, Sharma MC, Sarkar C. Morphology of angiogenesis in human cancer: a conceptual overview, histoprognostic perspective and significance of neoangiogenesis. *Histopathology* 2005; 46: 481-9.
  14. Rogatsch H, Hittmair A, Reissigl A, Mikuz G, Feichtinger H. Microvessel density in core biopsies of prostatic adenocarcinoma: a stage predictor? *J Pathol* 1997; 182: 205-10.
  15. Weidner N. Tumoral vascularity as a prognostic factor in cancer patients: the evidence continues to grow. *J Pathol* 1998; 184: 119-22.
  16. Bono AV, Celato N, Cova V, Salvatore M, Chinetti S, Novario R. Microvessel density in prostate carcinoma. *Prostate Cancer Prostatic Dis* 2002; 5: 123-7.
  17. El-Gohary YM, Silverman JF, Olson PR, Liu YL, Cohen JK, Miller R, Saad RS. Endoglin (CD 105) and vascular endothelial growth factor as prognostic markers in prostatic adenocarcinoma. *Am J Clin Pathol* 2007; 127: 572-9.
  18. Weidner N, Carroll PR, Flax J, Blumenfeld W, Folkman J. Tumor angiogenesis correlates with metastasis in invasive prostate carcinoma. *Am J Pathol* 1993; 143: 401-9.
  19. Erbersdobler A, Isbarn H, Dix K, Steiner I, Schlomm T, Mirlacher M et al. Prognostic value of microvessel density in prostate cancer: a tissue microarray study. *World J Urol* 2010; 28: 687-92.
  20. Tertiakova M, Antic T, Binder D, Kocherginsky M, Liao C, Taxy JB et al. Microvessel density is not increased in prostate cancer: digital imaging of routine sections and tissue microarrays. *Hum Pathol* 2013; 44: 495-502.
  21. Grivas N, Goussia A, Stefanou D, Giannakis D. Microvascular density and immunohistochemical expression of VEGF, VEGFR-1 and VEGFR-2 in benign prostatic hyperplasia, high-grade prostate intraepithelial neoplasia and prostate cancer. *Cent European J Urol* 2016; 69: 63-71.
  22. Carmeliet P, Jain RK. Molecular mechanisms and clinical applications of angiogenesis. *Nature* 2011; 47: 298-307.
  23. Hollingsworth HC, Kohn EC, Steinberg SM, Rosenthal ML, Merino MJ. Tumour angiogenesis in advanced stage ovarian carcinoma. *Am. J Pathol* 1995; 147; 33-41.
  24. Uzzan B, Nicolas P, Cucherat M, Perret GY. Microvessel density as a prognostic factor in women with breast cancer: a systematic review of the literature and meta-analysis. *Cancer Res.* 2004; 64: 2941-55.
  25. Kassouf W, Ismail HRA, Aprikian AG, Chevalier S (2004). Whole-mount prostate sections reveal differential endoglin expression in stromal, epithelial, and endothelial cells with the development of prostate cancer. *Prostate Cancer and Prostatic Dis* 2004; 7: 105-10.
  26. Silberman MA, Partin AW, Veltri RW, Epstein JI. Tumor angiogenesis correlates with progression after radical prostatectomy but not with pathologic stage in Gleason sum 5 to 7 adenocarcinoma of the prostate. *Cancer* 1997; 79: 772-9.
  27. Gettman M, Bergstralh E, Blute M, Zincke H, Bostwick DG. Prediction of patient outcome in pathologic stage T2 adenocarcinoma of the prostate: lack of significance for microvessel density analysis. *Urology* 1998; 51: 79-85.
  28. Rubin MA, Buyyounouski M, Bagiella E, Sharir S, Neugut A, Benson M et al. Microvessel density in prostate cancer: lack of correlation with tumor grade, pathologic stage, and clinical outcome. *Urology* 1999; 53: 542-7.
  29. Hlatky L, Hahnfeldt P, Folkman J. Clinical application of antiangiogenic therapy: microvessel density, what it does and doesn't tell us. *J Natl Cancer Inst* 2002; 94: 883-93.
  30. Steuber T, Helo P, Lilja H. Circulating biomarkers for prostate cancer. *World J Urol* 2007; 25: 111-19.

31. Chistiakov DA, Myasoedova VA, Grechko AV, Melnichenko AA, Orekhov AN. New biomarkers for diagnosis and prognosis of localized prostate cancer. *Semin Cancer Biol* 2018 doi.org/10.1016/j.semcancer.2018.01.012.
32. Bunting PS. Screening for prostate cancer with prostate-specific antigen: beware of biases. *Clin Chim Acta* 2002; 315: 71-91.
33. Kretschmer A, Tilki D. Biomarkers in prostate cancer – Current clinical utility and future perspectives. *Crit Rev Oncol Hematol* 2017; 120: 180-93.